

See discussions, stats, and author profiles for this publication at: <https://www.researchgate.net/publication/346305609>

Study of Anterior Commissure–Posterior Commissure Distance among Nepalese Cohort

Article in *Asian Journal of Neurosurgery* · January 2021

DOI: 10.4103/ajns.AJNS_232_20

CITATION

1

READS

64

9 authors, including:



Sambardhan Dabadi

Annapurna Neurological Institute & Allied Sciences

16 PUBLICATIONS 3 CITATIONS

SEE PROFILE



Raju Dhungel

Annapurna Neurological Institute & Allied Sciences

12 PUBLICATIONS 3 CITATIONS

SEE PROFILE



Pragya Dhungel

Annapurna Neurological Institute & Allied Sciences

4 PUBLICATIONS 7 CITATIONS

SEE PROFILE



Resha Shrestha

Annapurna Neurological Institute & Allied Sciences

32 PUBLICATIONS 57 CITATIONS

SEE PROFILE

Some of the authors of this publication are also working on these related projects:



Acute stroke [View project](#)



Starting DBS in Nepal published in IHRC [View project](#)

Study of Anterior Commissure-Posterior Commissure Distance among Nepalese Cohort

Abstract

Introduction: The main aim of this study is to determine the anterior commissure-posterior commissure (AC-PC) distance in Nepalese cohort and has comparison of intercommissural distance of Nepalese cohort with some other races. **Materials and Methods:** The 47 patients, with mean age of 50 years, included in the study had undergone DBS or lesioning (Pallidotomy). Data were collected through the magnetic resonance imaging under DBS protocol and the manipulation, marking of AC and PC was done in Inomed Planning Software (IPS). **Results:** The data revealed average AC-PC distance of Nepalese cohort to be 24.86 ± 2.08 mm, ranging from 16 mm to 30 mm. The study among 29 males and 18 females illustrated male to have longer AC-PC as compared to female (25.38 mm male and 24.02 mm female). The results also confirmed age related changes in AC-PC distance which was linearly increasing with the age. **Conclusion:** Comparison of data from other studies revealed Nepalese cohort to have almost similar AC-PC distance with Asian population, while that was longer in Caucasian and shorter in Hispanic Population.

Keywords: Anterior commissure, deep brain stimulation, lesioning, Nepalese, posterior commissure

Introduction

Human brain is one of the most complex structures and is highly variant among individuals in a group, ethnicity, age, and gender.^[1] Various atlas has been proposed and are in use to generalize and localize different regions in brain. However, such atlas sometimes is not able to map individual's brain because of variation in individual. One of the possible way to get over this problem is mapping anterior commissure-posterior commissure (AC-PC) distance and hence marking those regions with reference to AC-PC plane.^[2]

Anterior commissure refers to white matter fiber bundle connecting two cerebral hemisphere just ventral to supraoptic recess of third ventricle and column of the fornix.^[3] In axial magnetic resonance imaging (MRI) the AC can be viewed as bicycle handlebar, its peculiar shape makes it easily recognizable and hence is used as one of the reference points.^[4] Posterior commissure, on the other hand, corresponds to bundle of white matter fibers interconnecting two hemispheres just

dorsal to cerebral aqueduct. Located at the anterior margin of pineal region and close to superior colliculi, PC plays an important role in stereotactic procedures.^[4] AC and PC are clearly visible in high-resolution MRI images produced from 1.5T or 3T. The AC and PC line known as intercommissural line has been used as reference line for various stereotactic surgeries, human brain mapping, and medical image processing as these structures helps in indirect localization of intracerebral anatomy.^[2,5,6]

During the start of stereotactic-based neurosurgery in human by Spiegel and Wycis in 1947, external skull landmarks and brain atlas were used for localization of target.^[7] Later Talairach noticed that the internal nuclei coordinates are not always constant to external skull landmarks.^[8] Finally, in 1949, Schaltenbrand and Bailey developed a new atlas that included AC-PC distance and their coordinates as reference for localization of the target nuclei.^[9] In this study, we have used the same atlas for AC-PC distance measurement and the target mapping.

This is an open access journal, and articles are distributed under the terms of the Creative Commons Attribution-NonCommercial-ShareAlike 4.0 License, which allows others to remix, tweak, and build upon the work non-commercially, as long as appropriate credit is given and the new creations are licensed under the identical terms.

For reprints contact: reprints@medknow.com

How to cite this article: Dabadi S, Dhungel RR, Dhungel P, Gurung P, Shrestha R, Acharya S, *et al.* Study of anterior commissure-posterior commissure distance among Nepalese cohort. Asian J Neurosurg 2020;XX:XX-XX.

Submitted: 13-May-2020

Revised: 24-Jun-2020

Accepted: 02-Sep-2020

Published: ***

Sambardhan Dabadi,
Raju Raj Dhungel,
Pragya Dhungel,
Pritam Gurung¹,
Resha Shrestha¹,
Samir Acharya¹,
Pravesh Rajbhandhari¹,
Pranaya Shrestha¹,
Basant Pant¹

Departments of Biomedical Engineering and ¹Neurosurgery, Annapurna Neurological Institute and Allied Sciences, Maitighar, Kathmandu, Nepal

Address for correspondence:

Dr. Pritam Gurung,
Department of Neurosurgery,
Annapurna Neurological
Institute and Allied Sciences,
Maitighar, Kathmandu, Nepal.
E-mail: preetamgurung@
hotmail.com

Access this article online

Website: www.asianjns.org

DOI: 10.4103/ajns.AJNS_232_20

Quick Response Code:



Materials and Methods

Subjects

This study was approved by the Medical Ethics Committee of Annapurna Neurological institute and allied sciences. The medical ethics committee approved a waiver of consent for the collection of data. From 2016–2019, 47 subjects underwent intervention for either deep brain stimulation or lesioning (Pallidotomy). In a way, all the subjects were suffering from Parkinson or similar kind of movement disorder. 18 (32%) among 47 subjects were female and remaining 29 (68%) were male [Table 1]. The average age of the subjects was 50 ± 14 years, ranging from 10 to 74 years. The majority of the patients, 32% were between 50 and 60 years.

Image acquisition

Good quality of image plays a vital role in precisely locating anterior commissure and Posterior commissure. Images in this study were acquired from 3 tesla MRI. The images were taken in deep brain stimulation protocol [Table 2]. For precision and high quality of image some patients were scanned with slight sedation or under general anesthesia as almost all the subjects in this study are Parkinson's patient.

Image processing

High quality MRI images were burned in a compact disc and then loaded in a laptop. The images were then imported to Inomed Planning Software (IPS). IPS provides a platform for the user to manipulate digital imaging and communication in medicine images and helps planning the coordinates of target for deep brain stimulations. The AC and PC were first marked on T1 axial view [Figures 1 and 2]. Fusing the T1 and T2

sequence enables user to plan in either of the sequence and create better visualization of AC and PC. Once fused the AC and PC points are marked on either of sequences (T1 or T2).

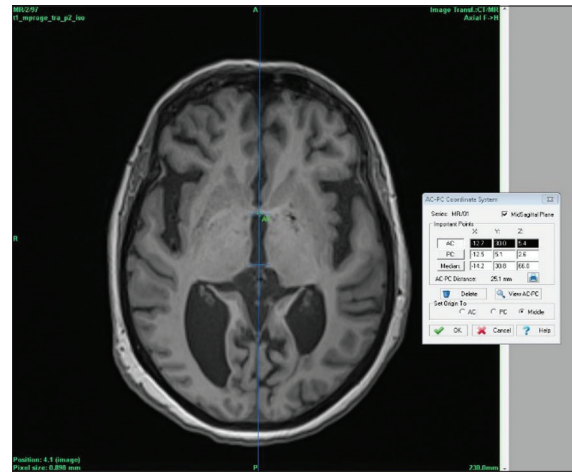


Figure 1: Marking of anterior commissure

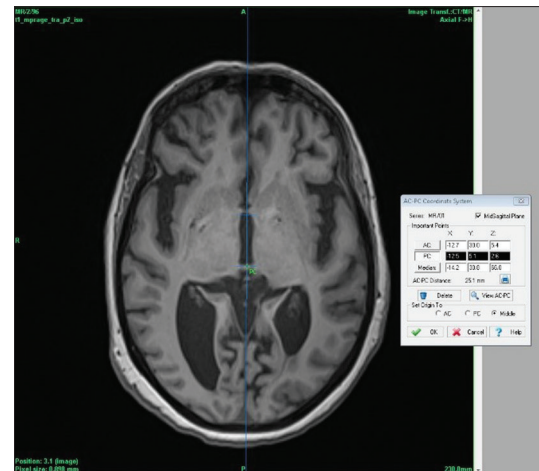


Figure 2: Marking of posterior commissure

Table 1: Selection of Patients

Gender	Number	Mean age (years)	Standard deviation
Male	29	49.90	15.25
Female	18	50.16	13.72
Total	47	50.03	14.85

Table 2: Magnetic Resonance Imaging Scan Parameters

Parameters	T1 Sequence	T2 Sequence
Scanner	Siemens 3T	Siemens 3T
Field of View (FoV)	230 mm	230 mm
Slice Thickness	1 mm	1 mm
TR	3300 ms	2200 ms
TE	404 ms	3.05 ms
No. of Slices	192	192
Orientation	Transversal (Axial)	Transversal (Axial)
SNR	1.00	1.03
Voxel size	0.9*0.9*1	0.9*0.9*1
Filter	Raw filter	Pre-scan Normalize

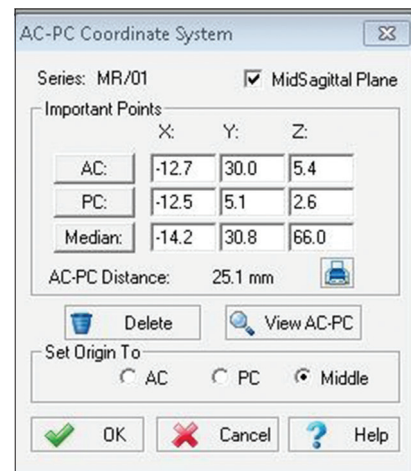


Figure 3: Anterior commissure-posterior commissure coordinate system

The AC-PC distance is self-measured by the system, once AC and PC are marked on the image. In general, the most preferred AC-PC distance is between 21 mm and 28 mm, however, any AC-PC beyond these limit can also be used [Figure 3]. The confirmation of accuracy of AC and PC is done through sagittal view [Figure 4]. In sagittal view, AC-PC and midline are confirmed if they are seen on same plane. Once confirmed, the targeting for required location is carried out.

Results

Forty-seven AC-PC distances were measured and then analyzed. The data illustrated average AC-PC distance for Nepalese people to be 24.86 mm with standard deviation of 2.08 mm, ranging from 16.3 mm to 30.1 mm. Further, data were classified based on the gender and age group, which demonstrated Nepalese male to have slightly larger AC-PC distance than female. The mean AC-PC distance for male with average age of 49.9 years was 25.38 ± 1.72 mm and that for the female with average age of 50.16 years was measured to be 24.02 ± 2.3 mm [Figure 5]. The observed values suggested males on average have 5.35% longer AC-PC distance as compared to female.

Same data were then analyzed based on the age groups [Table 3]. The data were classified into six age groups 10–19, 20–29 ... to 70–79. The graphical representation of AC-PC and age depicts the linear increase in AC-PC distance with age except for 50–59 years of group, where the AC-PC distance is decreased to 24.64 mm as compared to previous group 40–49 years with AC-PC distance of 25.08 mm [Figure 6].

Discussion

The above retrospective study conducted on 47 patients who underwent either DBS or lesioning of brain in Annapurna Neurological Institute and Allied Sciences, illustrates that the average intercommissural distance for Nepalese people to be 24.86 ± 2.03 mm. With the average age of the subjects taken to be 50 ± 14 years, the data categorized based on the age group suggest that the AC-PC distance is somehow proportional to the age. On the other hand, subcategory of data based on gender recommends Nepalese male to have slightly larger intercommissural

distance as compared to Nepalese female. Although the difference of mean age for male (49.9 years) and female (50.16 years) was not significant, the mean AC-PC distance was 25.38 ± 1.72 mm for male and 24.02 ± 2.32 mm for female. This may be the result of men having higher brain and cerebrospinal fluid (CSF) volume. A study on brain volume revealed men to have 91 ml higher brain volume and 20 ml greater CSF volume as compared to female.^[10]

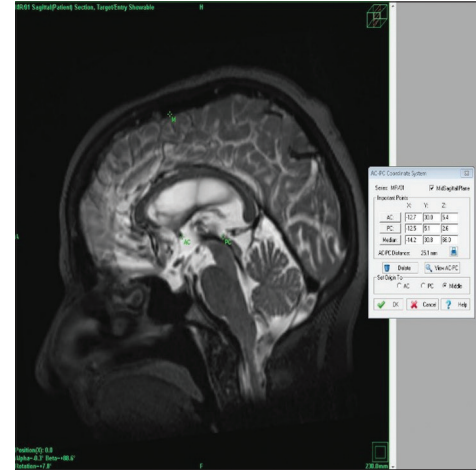


Figure 4: Anterior commissure-posterior commissure conformation in sagittal plane

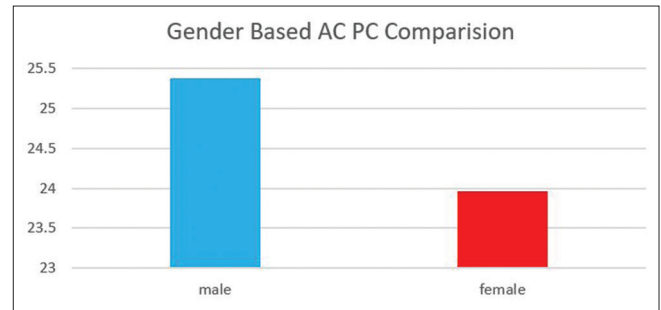


Figure 5: Anterior commissure-posterior commissure distance comparison on male and female

Table 3: Age based Anterior Commissure-Posterior Commissure distance

Groups (years)	Number	Mean (years)	SD (years)	AC-PC (mm)
10-19	2	11	±1	20.45±4.15
20-29	2	25	±3	22.40±1.40
30-39	6	34.33	±2.86	24.08±0.88
40-49	9	45.22	±2.65	25.08±0.75
50-59	15	53.53	±3.36	24.64±1.38
60-69	10	64.8	±2.63	26.23±1.87
70-79	3	72	±2	27.40±0.68

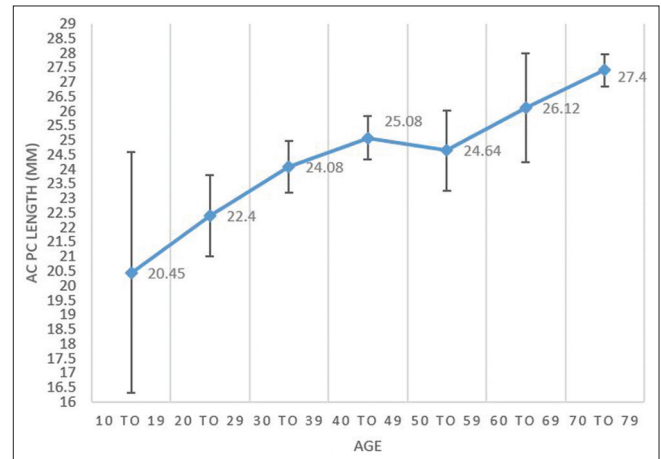


Figure 6: Anterior commissure-posterior commissure distance comparison with age

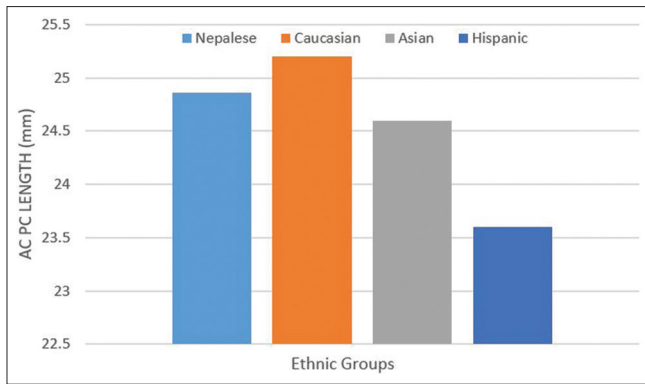


Figure 7: Comparison of anterior commissure-posterior commissure distance based on ethnic group

The results in coherence with a study by Lee *et al.* where the mean AC-PC distance for 12 Asian was obtained to be 24.6 ± 2.21 mm. This result suggests Nepalese to have nearly the same AC-PC distance as compared to Asian population. However, this distance was bit larger in Caucasian (European) population, which was reported to be 25.2 ± 2 mm, similar study done in Hispanic (Latino) group revealed the average AC-PC distance to be 23.6 ± 1.98 mm. These data reveal ethnicity related variation in AC-PC distance.^[11] Following graph depicts the AC-PC distance in various ethnic groups [Figure 7].

As we obtained the linear increase in AC-PC distance with age, Lee *et al.*, also have similar findings. The study on 211 patients in University of California, observed increase in AC-PC distance till the age of 75 years in Caucasian whereas in Hispanics the peak distance was at 45 which gradually decreased after that.^[11] One of the major factors for the increase in AC-PC distance with age is believed to be gradual loss of gray matter in brain between the ages of 20–50.^[12] In addition, the change in CSF region and decrease in cerebral hemisphere volume with age can be the reason for variation of the intercommissural distance.^[13]

With all these statistics, we can conclude that Nepalese cohort has an average distance of AC-PC and hence the average brain size as well.

Conclusions

The retrospective study done among 47 patients with DBS or lesioning procedure concluded Nepalese cohort to have an average AC-PC distance of 24.86 ± 2 mm. The study revealed that on average male to have slightly larger intercommissural distance than female of same age group, which was also supported by the facts presented by some papers. Data showed the mean AC-PC distance of male to be 25.38 mm while that for female to be 24.02 mm, which is 5% longer in males. The results also depicted

the linear relation of intercommissural distance with age. Further comparison with the data presented in other studies among Asian, Caucasian, and Hispanic population showed Nepalese to have almost similar AC-PC distance with Asian while that for Caucasian was 1.37% longer and for the Hispanic was 5.07% shorter.

Financial support and sponsorship

Nil.

Conflicts of interest

There are no conflicts of interest.

References

- Tang Y, Hojatkashani C, Dinov ID, Sun B, Fan L, Lin X, *et al.* The construction of a Chinese MRI brain atlas: A morphometric comparison study between Chinese and Caucasian cohorts. *Neuroimage* 2010;51:33-41.
- Liu Y, Dawant BM. Automatic detection of the anterior and posterior commissures on MRI scans using regression forests. *Conf Proc IEEE Eng Med Biol Soc* 2014;2014:1505-8.
- Peltier J, Vercllytte S, Delmaire C, Pruvo JP, Godefroy O, Gars DL. Microsurgical anatomy of the temporal stem: Clinical relevance and correlations with diffusion tensor imaging fiber tracking – Laboratory investigation. *J Neurosurg* 2010;112:1033-8.
- Blanchet B, Roland J, Braun M, Anxionnat R, Moret C, Picard L. The anatomy and the MRI anatomy of the interhemispheric cerebral commissures. *J Neuroradiol* 1995;22:237-51.
- Villemure JG, Marchand E, Peters T, Leroux G, Olivier A. Magnetic resonance imaging stereotaxy: Recognition and utilization of the commissures. *Appl Neurophysiol* 1987;50:57-62.
- Choi SH, Chi JG, Kim YB, Cho ZH. Anterior commissure – Posterior commissure revisited. *Korean J Radiol* 2013;14:653-61.
- Gildenberg PL. Spiegel and Wycis – The early years. *Stereotact Funct Neurosurg* 2001;77:11-6.
- Lacadie CM, Fulbright RK, Rajeevan N, Constable RT, Papademetris X. More accurate Talairach coordinates for neuroimaging using non-linear registration. *Neuroimage* 2008;42:717-25.
- Nowinski WL. Anatomical targeting in functional neurosurgery by the simultaneous use of multiple Schaltenbrand-Wahren brain atlas microseries. *Stereotact Funct Neurosurg* 1998;71:103-16.
- Gur RC, Mozley PD, Resnick SM, Gottlieb GL, Kohn M, Zimmerman R, *et al.* Gender differences in age effect on brain atrophy measured by magnetic resonance imaging. *Proc Natl Acad Sci U S A* 1991;88:2845-9.
- Lee TO, Hwang HS, Salles AD, Mattozo C, Pedroso AG, Behnke E. Inter-racial, gender and aging influences in the length of anterior commissure-posterior commissure line. *J Korean Neurosurg Soc* 2008;43:79-84.
- Miller AK, Alston RL, Corsellis JA. Variation with age in the volumes of grey and white matter in the cerebral hemispheres of man: Measurements with an image analyser. *Neuropathol Appl Neurobiol* 1980;6:119-32.
- Goyal MS, Vlassenko AG, Raichle ME. Sex differences in metabolic brain aging. *Proc Natl Acad Sci U S A* 2019;166:10634-5.