



## Transient Augmentation of Intraoperative Motor Evoked Potentials During Middle Cerebral Artery Aneurysm Surgery

Pritam Gurung<sup>1,4</sup>, Yasushi Motoyama<sup>1</sup>, Tsunenori Takatani<sup>2</sup>, Yoshiaki Takamura<sup>1</sup>, Yasuhiro Takeshima<sup>1</sup>, Ryosuke Matsuda<sup>1</sup>, Kentaro Tamura<sup>1</sup>, Shuichi Yamada<sup>1</sup>, Fumihiko Nishimura<sup>1</sup>, Ichiro Nakagawa<sup>1</sup>, Young-Su Park<sup>1</sup>, Masahiko Kawaguchi<sup>3</sup>, Hideyuki Ohnishi<sup>4</sup>, Hiroyuki Nakase<sup>1</sup>

■ **OBJECTIVE:** To study clinical significance of augmentation of intraoperative motor evoked potentials (MEPs) during direct open surgery for middle cerebral artery (MCA) aneurysms.

■ **METHODS:** Between 2009 and 2017, 134 MCA aneurysm surgeries were performed with intraoperative MEP monitoring. The frequency and cause of augmentation with >50% increase of MEP amplitude from baseline were studied. Factors associated with MEP augmentation were investigated.

■ **RESULTS:** MEP augmentation was demonstrated in 9 patients. All 9 events were observed just after application of the temporary clip to the parent artery. The ratio of the maximum amplitude to baseline was  $2.6 \pm 1.1$  at an mean of  $2.4 \pm 1.1$  minutes after parent artery occlusion. Ten patients who did not show MEP augmentation after parent artery occlusion were compared with the patients showing MEP augmentation. The distance of the temporary clip point from the midline was smaller in patients with MEP augmentation compared with patients without MEP augmentation ( $P = 0.033$ ).

■ **CONCLUSIONS:** MEP augmentation was thought to be an early ischemic sign preceding a significant decrease in MEPs during MCA aneurysm surgery. Transient augmentation of MEPs was more frequently observed in cases with a temporary clip applied to the more proximal part of the MCA.

### INTRODUCTION

Intraoperative monitoring of motor evoked potentials (MEPs) during surgery for aneurysms located in the internal carotid artery and middle cerebral artery (MCA) has been reported to be useful for preventing postoperative motor dysfunction.<sup>1,2</sup> MEP monitoring can detect a pyramidal tract insult as a decrease in the amplitude of the waveform elicited by electrical stimulation. A significant change of the amplitude has been defined as >50% decrease or disappearance in many reports.<sup>3-5</sup> However, a transient paradoxical increase in the amplitude of MEPs has been reported to be observed after ischemic stress and is recognized as an alarm corresponding to pyramidal tract injury.<sup>2,6</sup> However, MEP augmentation does not always occur after ischemic stress, and there have been no studies of the augmentation of intraoperative MEPs during aneurysm surgery. The primary aim of this study was to investigate the timing, frequency, and magnitude of MEP augmentation observed during surgery for MCA aneurysms. A secondary aim was to examine whether MEP augmentation was related to ischemia. Finally, the factors associated with the augmentation of MEPs were investigated.

### MATERIALS AND METHODS

#### Patient Selection and Study Design

This study was approved by the medical ethics committee of Nara Medical University. The medical ethics committee approved a waiver of consent for the collection of data as part of routine clinical care and quality control. Between 2009 and 2017, 331 patients underwent direct surgical intervention with intraoperative MEP monitoring for aneurysms; 141 of these patients harbored

#### Key words

- Augmentation of evoked potential
- Middle cerebral artery aneurysm
- Motor evoked potential
- Temporary clipping

#### Abbreviations and Acronyms

- 3D:** Three-dimensional
- CTA:** Computed tomography angiography
- DCS:** Direct cortical stimulation
- MCA:** Middle cerebral artery
- MEP:** Motor evoked potential
- TCS:** Transcranial stimulation

From the Departments of <sup>1</sup>Neurosurgery, <sup>2</sup>Central Laboratory, and <sup>3</sup>Anesthesiology, Nara Medical University, Kashihara; and <sup>4</sup>Department of Neurosurgery, Ohnishi Neurological Center, Akashi, Japan

To whom correspondence should be addressed: Yasushi Motoyama, M.D., Ph.D.  
[E-mail: myasushi@naramed-u.ac.jp]

Citation: World Neurosurg. (2019) 130:e127-e132.

<https://doi.org/10.1016/j.wneu.2019.06.004>

Journal homepage: [www.journals.elsevier.com/world-neurosurgery](http://www.journals.elsevier.com/world-neurosurgery)

Available online: [www.sciencedirect.com](http://www.sciencedirect.com)

1878-8750/\$ - see front matter © 2019 Elsevier Inc. All rights reserved.

aneurysms located in the MCA. Seven patients who did not undergo intraoperative monitoring of MEPs elicited by direct cortical stimulation (DCS), but only of MEPs elicited by transcranial stimulation (TCS), were excluded because serial records of MEPs during the microsurgical procedures were not available. Thus, the monitoring records of 134 patients with MCA aneurysms were retrospectively reviewed. MEP augmentation was defined as >50% increase in amplitude from the baseline. How many cases of augmentation occurred and in what situations MEP augmentation was observed were determined. In particular, the relationship to temporary clip application was studied. In cases with MEP augmentation, the timing, frequency, and magnitude of MEP augmentation were explored. Furthermore, in the patients who underwent temporary clipping, the factors associated with MEP augmentation were investigated by comparison between the groups with and without MEP augmentation to assess the mechanism of the augmentation.

#### Anesthesia and Measurement of Intraoperative MEPs

Anesthesia was induced with a bolus injection of propofol (1–2 mg/kg body weight), fentanyl (2 µg/kg body weight), and vecuronium (0.1 mg/kg body weight) or rocuronium (0.5–0.6 mg/kg body weight), and it was maintained with 40% oxygen, propofol (2.3–3.0 g/mL of a target-controlled infusion), fentanyl (total dose of 0.3–0.5 mg), and remifentanyl (0.05–0.2 mg/kg/minute). No muscle relaxants were used after induction and insertion of the endotracheal tube. After the trachea was intubated, the lungs were mechanically ventilated to maintain partial pressure of arterial carbon dioxide between 35 mm Hg and 40 mm Hg. Rectal temperature was maintained between 35.5°C and 37.0°C. Physiologic monitoring included electrocardiography, intra-arterial continuous blood pressure, oxygen saturation measurement by pulse oximetry, end-tidal carbon dioxide concentration, and rectal temperature.

In our institution, combined DCS and TCS was performed to elicit MEPs during aneurysm surgery.<sup>3</sup> In this study, data from MEPs elicited by DCS were compiled because serial records of MEPs elicited by DCS were available during the microscopic procedure. MEPs elicited by TCS were also monitored in many patients, but these data were intermittent during the microscopic procedures. For DCS, a strip of grid electrodes with 16 contacts (4 × 4 array, 5-mm-diameter contacts, spaced 10 mm apart, with one of the contacts serving as the anode) (Unique Medical Co. Ltd., Tokyo, Japan) was inserted into the subdural space after standard frontotemporal craniotomy to facilitate electrical stimulation of the hand portion of the primary motor cortex. A silver plate electrode placed at Fpz served as the cathode. First, the electrode strip was guided by the surgeon's anatomic knowledge to the primary motor cortex for placement. Second, the contact of the grid electrodes providing the largest MEP amplitude was chosen for stimulation during microsurgical procedures. Stimulation was performed with train-of-5 rectangular pulses with interstimulus intervals of 2 ms and a width of 0.2 ms. The intensity of DCS was initially set at 8 mA and increased in 1- or 2-mA steps to determine the threshold level. Intraoperatively, the motor cortex was stimulated at 2 mA above the threshold level, but the intensity did not exceed 30 mA in principle. If a motor response was not obtained with the first strip electrode position, the strip

was repositioned until a motor response could be obtained. Threshold levels were rechecked every 30 minutes, and baseline levels for MEPs were renewed. The ground electrode was placed on the left or right arm proximal to the elbow. Compound muscle action potentials were recorded from the skin over abductor pollicis brevis contralateral to the operated side. Evoked myographic responses were amplified with a 0.3- to 3-kHz bandpass filter and displayed on a monitor (Neuromaster MEE-1000; Nihon Kohden, Tokyo, Japan). MEP amplitude was defined as the range between the maximum positive and negative peaks of the polyphasic waveforms.

In ordinary operations, a significant change in MEPs is defined as complete disappearance or a decrease in amplitude of >50% of the baseline level. Likewise, >50% increase in the amplitude of MEPs was recorded as an abnormal finding; such changes were announced to the surgeon as an alarm. The baseline of the MEPs elicited by DCS were checked every 10 or 15 minutes during the microsurgical procedures. During the approach and the dissection of the aneurysm, MEPs elicited by DCS were checked at least every 5 minutes. Before temporary and permanent clip applications, MEPs elicited by DCS and TCS were obtained again as baseline. After clip application, MEPs elicited by DCS were meticulously checked at short intervals ranging from 20 seconds to 1 minute for 5 minutes. The surgeon was immediately informed of any abnormal and reproducible findings. The surgeon was also informed when no significant change in MEPs for >10 minutes after clip application was confirmed. Additional recordings were continued every 5 minutes up to dural closure.

#### Comparison Between Patients with and without MEP Augmentation After Temporary Clipping

MEP augmentation was demonstrated in 9 patients after application of the temporary clip to the parent artery. Whether such events were related to ischemia was then confirmed based on the operation and monitoring records. Ten patients who underwent temporary clip application to the parent artery did not show MEP augmentation, and their characteristics and the parameters of their MEPs were compared with the 9 patients with MEP augmentation to identify associated factors. MEP parameters included stimulus strength, baseline amplitude, location of the temporary clip, maximum amplitude and its ratio to the baseline, minimum amplitude and its ratio to the baseline, and duration of ischemia due to temporary clip application.

#### Location and Duration of Temporary Clip Application

Intraoperative video data were retrospectively retrieved from the video library of the Department of Neurosurgery, Nara Medical University. Scenes showing application of the temporary clip were identified, and the images were captured to determine to which part of the MCA the temporary clip was applied. The precise duration of temporary occlusion of the MCA was also counted on video. Furthermore, three-dimensional (3D) computed tomography angiography (CTA) imaging and digital subtraction angiography were reviewed to find intraoperative images showing the point at which the temporary clip was applied to judge whether lenticulostriate arteries were involved by the temporary clip, thus causing blood flow insufficiency to the subcortical gray matter. According to these data, the

estimated point where the temporary clip was applied was plotted on the 3D CTA image. The distance of that point from the midline was then measured on 3D CTA. The midline was defined by the line joining the bases of the crista galli and the vomer bone on the nasal floor in the coronal image.

### Statistical Analysis

Statistical comparisons between the 2 groups were performed using Mann-Whitney *U* test for continuous variables and Fisher exact test for the dichotomous variables with EZR (Saitama Medical Center, Jichi Medical University, Saitama, Japan), which is a graphical user interface for R (R Foundation for Statistical Computing, Vienna, Austria). Significance was set at  $P < 0.05$ .

## RESULTS

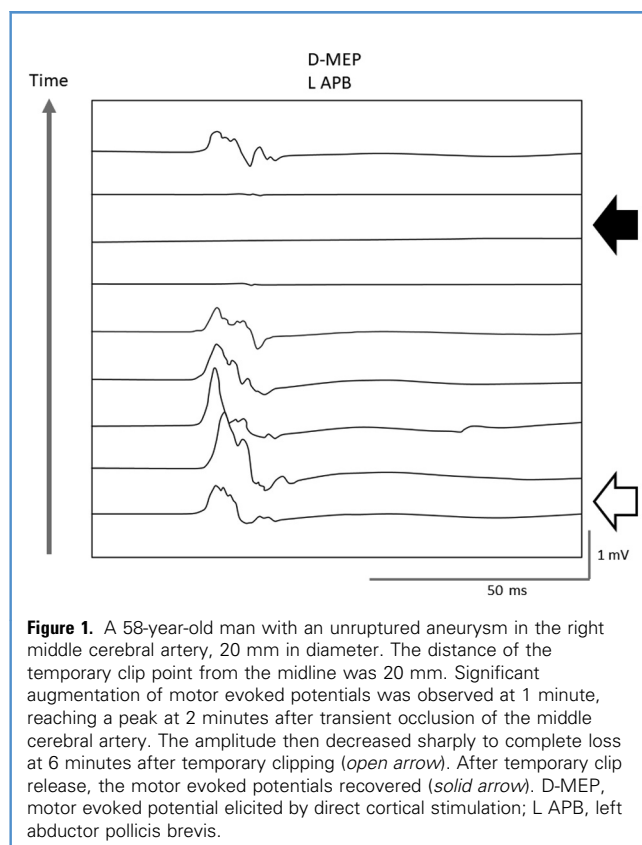
### Patient Characteristics

Serial MEPs were available for 134 patients (96 women, 38 men; mean age  $65.1 \pm 9.5$  years; age range, 35–85 years) with an MCA aneurysm underwent direct surgery with MEPs elicited by DCS. There were 4 ruptured and 130 unruptured MCA aneurysms. Two patients had preoperative mild hemiparesis on the side contralateral to the lesion. The 134 aneurysms included 1 recurrent aneurysm, 1 fusiform aneurysm, and 3 distally located aneurysms. Clipping was performed in 133 patients, and wrapping was performed in 1 patient. For 1 patient with a recurrent large aneurysm, additional extracranial-to-intracranial bypass surgery was performed.

Temporary clipping was used in 19 patients. In 18 patients, temporary clips were applied to the M1 trunk of the MCA before neck clipping. In the patient with a recurrent large aneurysm, a temporary clip was applied to the M2 branch of the MCA for the construction of the extracranial-intracranial bypass. In this patient, the first application of the temporary clip led to disappearance of MEPs, so the temporary clip was released before arteriotomy. In 20 patients, intraoperative MEPs showed significantly reduced amplitudes. Causative procedures included temporary clip application, inappropriate neck clipping, and excessive brain retraction. Although the significant decreases of MEPs were transient in almost all patients, MEPs remained significantly decreased at the end of microsurgery in only 1 patient. Postoperative deterioration of motor function was found in 3 patients with significant intraoperative changes of MEPs. However, hemiparesis in those 3 patients was transient and improved to the preoperative level of motor function within 1 month.

### MEP Augmentation

Of 134 patients, 9 showed  $>50\%$  increase of amplitude of MEPs from baseline (6.7%) (Figure 1). All 9 events with MEP augmentation were observed within 4 minutes after the temporary clips were applied to the parent artery. The mean duration of temporary occlusion of the MCA was  $4.2 \pm 1.3$  minutes (range, 2–7 minutes). The mean time from temporary clip application to the maximum amplitude of MEPs was  $2.5 \pm 1$  minutes (range, 1–4 minutes). The mean ratio of the maximum amplitude to baseline was  $2.6 \pm 1.1$  (range, 1.5–4.7). Of the 9 patients,  $>50\%$  decrease of MEPs was subsequently



**Figure 1.** A 58-year-old man with an unruptured aneurysm in the right middle cerebral artery, 20 mm in diameter. The distance of the temporary clip point from the midline was 20 mm. Significant augmentation of motor evoked potentials was observed at 1 minute, reaching a peak at 2 minutes after transient occlusion of the middle cerebral artery. The amplitude then decreased sharply to complete loss at 6 minutes after temporary clipping (*open arrow*). After temporary clip release, the motor evoked potentials recovered (*solid arrow*). D-MEP, motor evoked potential elicited by direct cortical stimulation; L APB, left abductor pollicis brevis.

observed in 7 patients, including complete loss in 4 patients. The minimum decrease of MEPs was always observed after MEP augmentation (Table 1).

Ten patients who underwent temporary clipping during surgery did not show  $>50\%$  increase of MEPs (Figure 2). Thus, in patients who underwent temporary clip application, MEP augmentation occurred in 9 of 19 patients (47.4%). In the 10 patients, the time when the maximum amplitude of MEPs was recorded and its ratio to the baseline were  $2.4 \pm 1.4$  minutes and  $1.1 \pm 0.2$ , respectively. Six of these 10 patients subsequently showed  $>50\%$  decrease of MEPs; in 1 of the patients, there was complete loss of MEPs.

The patients who underwent temporary clip application were divided into patients with MEP augmentation (group A) and patients without MEP augmentation (group B). There were no differences between the 2 groups except that the distance of the temporary clip point from the midline was shorter in group A than in group B. Postoperative hemiparesis was observed transiently in only 1 patient in group A (Table 2). In this series, temporary clips were applied at various points along the MCA. The locations of application of the temporary clip were divided into 3 parts: proximal part of the horizontal segment of the MCA (proximal M1), distal part of M1 (distal M1), and insular segment of the MCA (M2). The locations where the temporary clips were applied were checked by inspecting individual intraoperative videos. The temporary clips were applied just after the

Table 1. Characteristics of Patients Showing Augmentation of Motor Evoked Potentials

Patient	Age (years)	Sex	Baseline Amplitude (mV)	Stimulation (mA)	Maximum Amplitude (mV)	Ratio of Maximum to Baseline	Maximum Time (minutes)	Minimum Amplitude (mV)	Ratio of Minimum to Baseline	Minimum Time (minutes)	Event	Duration of Temporary Clip (minutes)
1	68	Male	1.03	20	2.54	2.47	3	1.62	1.57	10	Temporary clip	2
2	70	Female	0.19	20	0.49	2.58	4	0.26	1.37	7	Temporary clip	4
3	60	Male	1.03	14	1.93	1.87	2	0.16	0.16	12	Temporary clip	4
4	58	Female	0.75	22	1.92	2.56	4	0	0	6	Temporary clip	7
5	66	Male	0.84	20	3.93	4.68	2	0	0	4	Temporary clip	5
6	65	Male	1.17	25	2.2	1.88	3	0.54	0.46	6	Temporary clip	4
7	66	Male	2.3	21	4.2	1.83	2	0	0	7	Temporary clip	4
8	68	Female	0.65	20	2.82	4.34	1	0	0	6	Temporary clip	5
9	48	Female	1.62	11	2.435	1.51	1	0.67	0.41	3	Temporary clip	3
Mean ± SD	63.2 ± 6.5	44.4% female	1.06 ± 0.6	19.2 ± 4	2.5 ± 1	2.6 ± 1.1	2.4 ± 1.1	0.46 ± 0.5	0.44 ± 0.6	6.8 ± 2.6	100%	4.2 ± 1.3

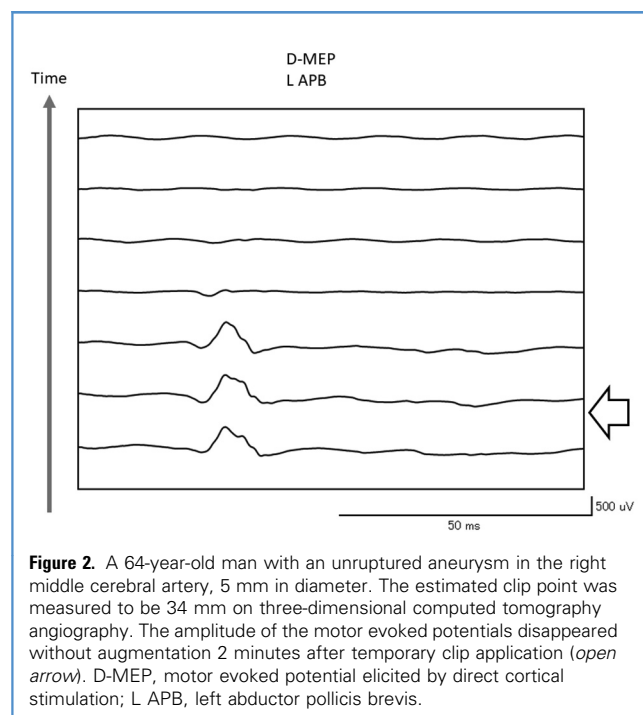
bifurcation of the internal carotid artery or at proximal M<sub>1</sub> in 7 patients and at distal M<sub>1</sub> in 11 patients. One patient had a temporary clip applied at M<sub>2</sub>. In group A, temporary clips were applied at proximal M<sub>1</sub> in 5 patients and at distal M<sub>1</sub> in 4 patients. In group B, 2 patients had clipping at proximal M<sub>1</sub>, 7 patients had clipping at distal M<sub>1</sub>, and 1 patient had clipping at M<sub>2</sub> (Table 2). The distance of the estimated temporary clip point, plotted on the 3D CTA image, from the midline was measured. In group A, the mean distance was 22.6 ± 3.8 mm (range, 18–29 mm). In group B, the mean distance was 28 ± 6.2 mm (range, 16–38 mm). Analysis of the distance of the temporary clip points from the midline showed a significant difference between the 2 groups ( $P = 0.033$ ).

## DISCUSSION

In the present study, MEP augmentation was observed only just after the application of a temporary clip to the parent artery during MCA aneurysm surgery. When augmentation and a significant decrease of MEPs occurred, augmentation always preceded the decrease of MEPs. In 2 patients who did not show a significant decrease of MEPs, the duration of MCA occlusion by temporary clip application was 2 minutes and 4 minutes, respectively. Had the duration of MCA occlusion been longer in these 2 patients, a significant decrease of MEPs might have been seen. Therefore, MEP augmentation could be interpreted to be an early ischemic sign. Of the 19 patients who underwent temporary clip application, MEP augmentation occurred in 9 (47.4%). MEP augmentation was not always observed after ischemic stress. The mechanism of augmentation of MEPs is unknown, and the factors associated with the phenomenon have never been reported clinically.

In an experimental study using feline spinal cord affected by ischemia, Iizuka and Kurokawa<sup>7</sup> reported that the augmentation of MEPs was correlated with the strength of stimulation. According to the authors, this suggested a significant role of the subliminal fringe and an increased excitability of nerve fibers under ischemia in this phenomenon. However, in the present study, there was no significant difference between groups A and B in the strength of stimulation eliciting MEPs.

From another perspective, it has been suggested that the increase of MEPs is caused by enhanced cortical excitability due to disinhibition of inhibitory synapses in an experimental study using a rat model.<sup>8</sup> It is difficult to prove that inhibitory synapses of the motor system are disinhibited during clinical observation. However, the present data showed that the augmentation of MEPs was more frequently observed in cases with a temporary clip applied to the more proximal part of the MCA. Temporary clip application more proximal to the midline would imply that a wider area was affected by transient ischemic stress. The wider area of ischemia could include the premotor area and the supplementary motor area, which have inhibitory neural projections. The corpus striatum of the basal ganglia might also be included if a temporary clip is applied to the proximal side of the M<sub>1</sub> trunk, which involves the lenticulostriate arteries. In the present study, temporary clips were placed at proximal M<sub>1</sub> in 5 of 9 patients (56%) in group A, but in only 2 of 10 patients (20%) in group B.



### MEP Augmentation Before Decrease of MEPs

In an experimental study, MEP augmentation occurred in the reperfusion period after transient MCA occlusion.<sup>8</sup> In the present study, however, augmentation always preceded a decrease of MEPs. MEP augmentation is observed in the early period after temporary clip application. If augmentation was due to disinhibition of inhibitory synapses, the precedence of augmentation over a decrease of MEPs could be explained by the difference in tolerance for ischemia between the pyramidal tract and inhibitory interneurons. Gray matter tolerates ischemic insults less than white matter. Furthermore, high ischemic vulnerability of glutamatergic synapses of excitatory pyramidal cells to inhibitory interneurons relative to  $\gamma$ -aminobutyric acidergic synapses has been demonstrated previously in vitro: in rat hippocampal slices, anoxia disconnected inhibitory interneurons from excitatory inputs.<sup>9-11</sup> Transient global ischemia would lead to laminar necrosis in the cerebral cortex and cavitation of the basal ganglia. Collateral flow in the cerebral cortex develops through not only the circle of Willis but also leptomeningeal anastomoses. The basal ganglia, however, are mainly supplied by terminal medullary vessels, such as the lenticulostriate arteries. If the temporary clip was applied at proximal M1, lateral striate arteries would be supplied only by retrograde blood flow through leptomeningeal anastomoses. Therefore, transient focal ischemia of the MCA would primarily cause damage to the caudate putamen.<sup>12</sup>

The inferior ability of subcortical gray matter to tolerate ischemic stress could indicate that the phenomenon observed in the early stage after ischemic stress caused by temporary clip application at proximal M1 would be associated with dysfunction of subcortical gray matter. We hypothesized that paradoxical

**Table 2.** Comparison Between Groups with and without Augmentation of Motor Evoked Potentials After Temporary Clip

Variable	Patients with Augmentation (Group A)	Patients without Augmentation (Group B)	P Value
Number of patients	9	10	
Patient age, years	63.2 ± 6.5	61.4 ± 7.2	0.712
Female patients, %	44.4	80	0.17
Temporary clip			
Location			
Proximal M1	5	2	
Distal M1	4	7	
M2	0	1	
Duration, minutes	4.2 ± 1.3	4.3 ± 1.6	0.802
Length of temporary clip point from midline, mm	22.6 ± 3.8	28 ± 6.2	0.033*
Baseline stimulation, mA	19.2 ± 4	20.2 ± 5	0.769
Baseline amplitude, mV	1.1 ± 0.6	1.5 ± 1.4	0.902
After temporary clip			
Maximum amplitude, mV	2.5 ± 1	1.8 ± 1.8	0.079
Maximum rate per baseline	2.6 ± 1.1	1.1 ± 0.2	<0.01
Time, minutes	2.4 ± 1.1	2.4 ± 1.4	0.672
Minimum amplitude, mV	0.5 ± 0.5	0.6 ± 0.8	0.174
Minimum rate per baseline	0.4 ± 0.6	0.4 ± 0.3	0.434
Time, minutes	6.8 ± 2.6	5.2 ± 2.6	0.107
Outcome			
Transient hemiparesis	1(11.1%)	0	
Permanent hemiplegia	0	0	

Mann-Whitney *U* test was used for statistical analysis.  
\*Statistically significant.

augmentation followed by a decrease of MEPs after temporary clip application might be due to ischemia of subcortical gray matter. The change in blood flow in the MCA after temporary clip application is difficult to measure directly in humans; especially challenging is distinguishing the cerebral cortex from subcortical basal ganglia during surgery. Therefore, the distance of the temporary clip point from the midline was used as the quantitative indicator to evaluate estimated blood flow reduction beyond the temporary clip point. Indeed, the development of leptomeningeal anastomoses and the circle of Willis strongly affect the ability to tolerate ischemic insults. Thus, the distance of the temporary clip point from the midline is not the absolute value representing MCA flow directly but only an indicator.

When MEP augmentation occurs during surgery, especially after temporary clip application, it will be interpreted as an early sign of ischemia that precedes a significant decrease of MEPs without any

countermeasures. Furthermore, MEP augmentation might suggest that the lenticulostriate arteries contributing to subcortical gray matter are ischemic. In the present study, there were no significant differences in clinical outcome between groups A and B. However, MEP augmentation is thought to be useful as an alarm indicating ischemia.

### Limitations

This study has several limitations. The first is its retrospective, single-center design. The second is the small patient pool. A significant difference was seen only in the distance from the midline of the temporary clip point between groups A and B. To examine the correlation between the point of temporary clip application and the intensity of augmentation, a much greater number of cases would be required. Therefore, to strengthen the evidence for quantitative measurement of the distance from the midline of the clip point, the rates of the segments of the MCA where the temporary clip was applied were calculated and compared between groups A and B. According to the protocol, transcranial MEPs were less frequently checked during microscopic procedures. Therefore, when we use transcranial MEPs during aneurysm surgery, we cannot say that augmentation of MEPs has the same meaning as that observed with direct MEPs in the present study. However, MEP augmentation was also

recognized by transcranial electrical stimulation in at least 1 patient, in whom direct MEPs showed the same transient augmentation.

### CONCLUSIONS

Transient augmentation of MEPs occurred occasionally after temporary occlusion during MCA aneurysm surgery. When augmentation and a significant decrease of MEPs were observed, augmentation of MEPs always occurred first. Transient augmentation of MEPs was more frequently observed in patients with a temporary clip applied to the more proximal part of the MCA. When MEP augmentation is encountered during surgery, it should be considered an early ischemic sign.

### ACKNOWLEDGMENTS

The authors express their gratitude to the staff of the intraoperative neuromonitoring team from Nara Medical University for measuring and recording neurophysiologic monitoring in the operating room. The authors are also greatly indebted to Mr. Dmitriy Kravchenko from Bonn University for his proofreading, which has profoundly improved this article.

### REFERENCES

1. Suzuki K, Kodama N, Sasaki T, et al. Intraoperative monitoring of blood flow insufficiency in the anterior choroidal artery during aneurysm surgery. *J Neurosurg.* 2003;98:507-514.
2. Horiuchi K, Suzuki K, Sasaki T, et al. Intraoperative monitoring of blood flow insufficiency during surgery of middle cerebral artery aneurysms. *J Neurosurg.* 2005;103:275-283.
3. Motoyama Y, Kawaguchi M, Yamada S, et al. Evaluation of combined use of transcranial and direct cortical motor evoked potential monitoring during unruptured aneurysm surgery. *Neurol Med Chir (Tokyo).* 2011;51:15-22.
4. Chung J, Park W, Hong SH, et al. Intraoperative use of transcranial motor/sensory evoked potential monitoring in the clipping of intracranial aneurysms: evaluation of false-positive and false-negative cases. *J Neurosurg.* 2019;130:936-948.
5. Szelenyi A, Langer D, Kothbauer K, De Camargo AB, Flamm ES, Deletis V. Monitoring of muscle motor evoked potentials during cerebral aneurysm surgery: intraoperative changes and postoperative outcome. *J Neurosurg.* 2006;105:675-681.
6. Fujii M, Nomura S, Imoto H, et al. The usefulness of the intraoperative monitoring of the motor evoked potential (MEP) with D-wave in aneurysm surgery. *Surg Cereb Stroke.* 2008;36:373-379.
7. Iizuka T, Kurokawa T. Transient augmentation of the evoked spinal cord and peripheral nerve action potentials through ischemia [in Japanese]. *Nihon Seikeigeka Gakkai Zasshi.* 1982;56:163-170.
8. Bolay H, Gürsoy-Özdemir Y, Ünal I, Dalkara T. Altered mechanisms of motor-evoked potential generation after transient focal cerebral ischemia in the rat: implications for transcranial magnetic stimulation. *Brain Res.* 2000;873:26-33.
9. Khazipov R, Congar P, Ben-Ari Y. Hippocampal CA1 lacunosum-moleculare interneurons: comparison of effects of anoxia on excitatory and inhibitory postsynaptic currents. *J Neurophysiol.* 1995;74:2138-2149.
10. Zhu PJ, Krnjevic K. Anoxia selectively depresses excitatory synaptic transmission in hippocampal slices. *Neurosci Lett.* 1994;166:27-30.
11. Hofmeijer J, van Putten MJ. Ischemic cerebral damage: an appraisal of synaptic failure. *Stroke.* 2012;43:607-615.
12. Fujioka M, Taoka T, Matsuo Y, Hiramatsu KI, Sakaki T. Novel brain ischemic change on MRI. Delayed ischemic hyperintensity on T1-weighted images and selective neuronal death in the caudoputamen of rats after brief focal ischemia. *Stroke.* 1999;30:1043-1046.

*Conflict of interest statement: This work was supported by a Grant-in-Aid for Scientific Research from the Ministry of Education, Culture, Sports, Science, and Technology of Japan (Grant No. 17K10904).*

*Received 15 February 2019; accepted 1 June 2019*

*Citation: World Neurosurg. (2019) 130:e127-e132.*

*https://doi.org/10.1016/j.wneu.2019.06.004*

*Journal homepage: [www.journals.elsevier.com/world-neurosurgery](http://www.journals.elsevier.com/world-neurosurgery)*

*Available online: [www.sciencedirect.com](http://www.sciencedirect.com)*

*1878-8750/\$ - see front matter © 2019 Elsevier Inc. All rights reserved.*