

See discussions, stats, and author profiles for this publication at: <https://www.researchgate.net/publication/346934475>

# Neurological Manifestations Presenting in COVID 19:A Case Series from Nepal

Article · December 2020

DOI: 10.47755/JClinCaseStudRev.2020.1.005

CITATIONS

0

READS

83

9 authors, including:



**Avinash Chandra**

Annapurna Neurological Institute & Allied Sciences

92 PUBLICATIONS 383 CITATIONS

[SEE PROFILE](#)



**Shreejana Thapa**

5 PUBLICATIONS 0 CITATIONS

[SEE PROFILE](#)



**Ayush Chandra**

Pokhara Academy of Health Sciences

40 PUBLICATIONS 27 CITATIONS

[SEE PROFILE](#)



**Basant Pant**

Annapurna Neurological Institute & Allied Sciences

134 PUBLICATIONS 809 CITATIONS

[SEE PROFILE](#)

Some of the authors of this publication are also working on these related projects:



Case report [View project](#)



neurocysticercosis presentation [View project](#)

## Neurological Manifestations Presenting in COVID 19: A Case Series from Nepal

Avinash Chandra<sup>1</sup>, Shreejana Thapa<sup>1</sup>, Ayush Chandra<sup>2,3\*</sup>, Anik Jha<sup>1</sup>, Shilpa Giri<sup>1</sup>, Sudikshya Acharya<sup>1</sup>, Subash Paudel<sup>1</sup>, Nimisha Risal<sup>1</sup>, Basant Pant<sup>1</sup>

<sup>1</sup>Department of Neurology, Annapurna Neurological Institute and Allied Sciences, Maitighar, Kathmandu, Nepal

<sup>2</sup>Department of Neurology, Tianjin Medical University, Tianjin, PR China

<sup>3</sup>Department of Neurology, Multiple Sclerosis Society Nepal, Kathmandu, Nepal

\*Correspondence to: Ayush Chandra, Department of Neurology, Tianjin Medical University, Tianjin, PR China, E-mail: ayushchandra1995@yahoo.com

Received: 19 November 2020; Accepted: 03 December 2020; Published: 10 December 2020

Copyright: © 2020 ChandraA, et al. This is an open-access article distributed under the terms of the Creative Commons Attribution License, which permits unrestricted use, distribution, and reproduction in any medium, provided the original author and source are credited.

### Abstract

**Background:** Nepal comes in the low-income nation with the health system working in very strenuous situation. Most of the health care is borne by the individual themselves. Even though geographically sitting close to China (where COVID-19 cases started) and India (where COVID-19 cases surged to the highest level), Nepal has been facing COVID-19 infection only recently. The exponential rise in cases, have brought the health system to the chaotic level. The late appearance of COVID-19 in Nepal has allowed us to understand more of the COVID-19 squeal.

**Methods:** A retrospective cases series of patients diagnosed with COVID-19 using reverse transcriptase polymerase chain reaction (rt-PCR) in nasopharyngeal swabs, who either first came with neurological symptoms or other symptoms were analyzed. The neurological disorder was diagnosed clinically with positive laboratory or imaging evidence.

**Results:** Four patients were identified, median age 43.5 (range 28-57). Neurological disorders that were noted were seizure, ischemic stroke, and Guillain-Barre syndrome (GBS). All patients had history of taking antihypertensive drugs. None of them had any family history and were otherwise healthy. The blood work up of all these patients was within normal limits, except in one patient who had marginally high glycosylated hemoglobin (HbA1C 7.2%).

**Conclusion:** COVID-19 can present with different kinds of symptoms. We believe this case series is first being reported from Nepal. Recently neurological disorder has been reported quite often. Hence, it is imperative that regardless of etiology, COVID-19 should be considered in the differential diagnosis for patients presenting with neurological disorder during the pandemic. Early consideration of COVID-19 thus may lead to earlier detection and appropriate precautions.

**Keywords:** COVID-19; Coronavirus; Cerebrovascular disease; Neurological disorder; Ischemic stroke; Paralysis

### Introduction

The World Health Organization (WHO) declared human corona virus disease (COVID-19) outbreak as a pandemic on March 11, 2020. Nepal first faced COVID-19 case (single case) back in February 2020 while the pandemic wave has hit the nation only from last 3 months and we are seeing the exponential rise in the COVID-19 cases. The most reliable and commonly used lab investigation for detection of COVID-19 is real time rt-PCR [1]. Despite the fast-growing research and concentrated attention of the world to the COVID-19 pandemic, the full spectrum of COVID-19 is not fully revealed yet [2, 3]. Some patients may have no clinical symptoms while some exhibit uncommon new symptoms. Recent scientific evidence suggests that SARS-CoV-2 virus has neuroinvasive potential, like other coronaviruses [4]. Hence, it seems


that it was only a matter of time before neurological complications were reported [4, 5]. Neurological disorders especially stroke, neuromuscular disorders, and meningoencephalitis were expected to occur more frequently than other neurological problems [3]. A systemic review concluded that large vessel stroke, flaccid paralysis like GBS, meningoencephalitis were among commonly encountered problems [6]. Here, in this case series we have presented some common and some uncommon neurological disorders due to COVID-19 infection.

### Case 1

A 55-year-old male, with the past history of controlled hypertension since 10 years, was brought by the family relative to the emergency department due to the loss of consciousness (LOC) which

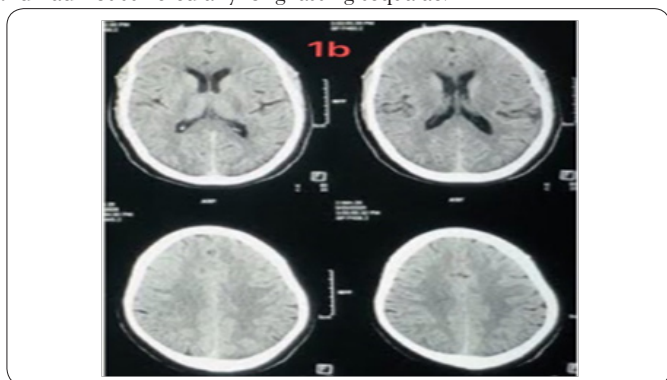
was associated with the abnormal body movement. The first event happened while at home. According to the informant, this was first time ever for the patient. No one in his family either had experienced this kind of event. The LOC lasted for roughly 5 minutes and followed by one brief (<5 minutes) episode of generalized tonic-clonic movement of the body (GTCS). There was no reported history of tongue bite, bowel, or bladder incontinence but there was frothing from the mouth and clenching of teeth for few seconds.

The second episode of GTCS had occurred while presenting at the local hospital nearby (100 meters distance from the place of the patient). After another episode of GTCS, the patient was referred to Emergency department (ER) at our center. In-between these two events, patient had complained of shortness of breath (SOB) and was maintained on oxygen supplementation through nasal prongs. Upon arrival at our center, the patient had high grade fever (102-degree Fahrenheit), he was drowsy and on oxygen supplementation. He was not having seizure at the time of arrival. The arterial blood gas (ABG) analysis was not significant (pH was 7.392, bicarbonate HCO<sub>3</sub> 21.9). Other lab reports in emergency setting also showed non-significant (except that the random blood sugar was bit higher side 187mg/dl). After a few steps of primary management, he regained consciousness and GCS was 15/15. ABG was repeated with several hours apart and it showed no remarkable abnormality (Figure 1a).



**Figure 1(a):** Arterial Blood Gas (ABG) analysis showing no significant abnormality

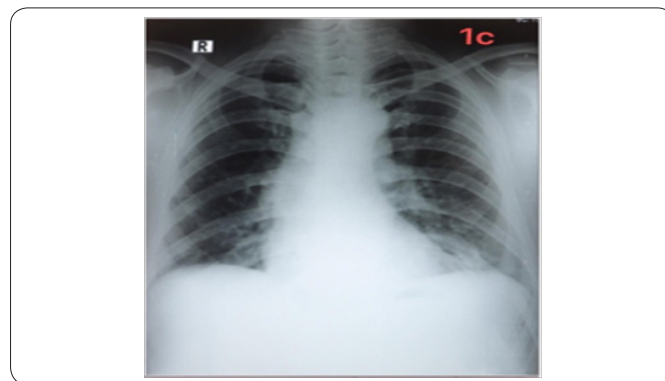
The oxygen saturation however was still maintained with oxygen supplementation (2L/min). He had history of trauma several years back and had not suffered any long lasting sequelae.



**Figure 1(b):** CT Scan of Head (axial cut), showing normal CT Head CT was done back then (according to the patient) and it had not shown any injury inside his head, however he had sustained some

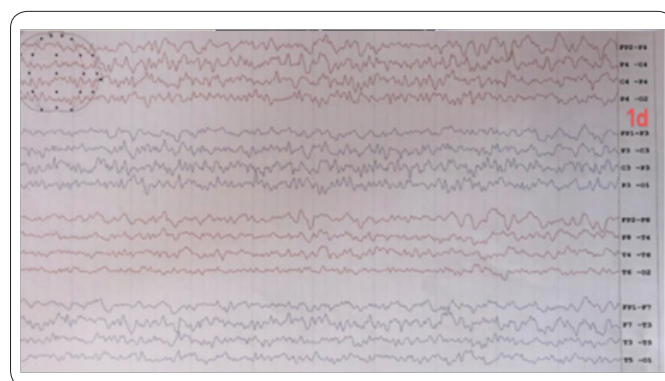
deep cut injury over the skull and had received sutures (Figure 1b).

At the ER, he underwent head CT, Chest X-ray, Electro-Encephalogram (EEG), and blood investigations were done. Blood investigations including electrolytes were non remarkable. Chest X-ray also showed no clear abnormality (Figure 1c).



**Figure 1(c):** Chest X-ray showing mild unfolding of aorta

EEG was done few hours after intervention with injection Lorazepam and antiepileptic medicine. No overt seizure was seen at that time, but the EEG showed an interictal seizure pattern (Figure 1d). CT head for brain parenchyma was normal (Figure 1b).



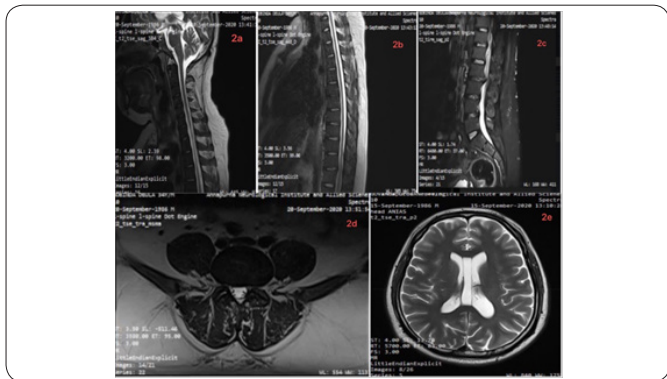
**Figure 1(d):** Electro-Encephalogram (EEG) showing Interictal seizure pattern

Patient was initially given lorazepam 2mg intravenous (i.v.) bolus with phenytoin 600mg i.v. bolus and later maintained with 100mg i.v. 8 hr. The seizure was well controlled and did not show any recurrence. The rt-PCR report for COVID-19 showed positive. He was maintained on phenytoin (100 mg 8 hourly) and was transferred to the COVID care unit and managed symptomatically and no recurrence of seizure was noted.

## Case 2

A 34-year-old gentleman came to ER with the complaint of weakness in limbs severe enough to walk independently. The weakness was progressive in nature. He initially noticed fatigueness and the weakness was milder in his lower limbs which he attributed to prolonged walking 6 days back. Then he noticed moderate weakness in his hands while lifting load in the following second day. The weakness progressively increased and he visited the local health clinic where he was advised for X-ray of cervical spine which appeared normal. Then he was referred to the hospital for the traditional practice (Ayurveda and acupuncture). He stayed for few days in that hospital for receiving Ayurveda medicine

and acupuncture with no improvement. The MRI of whole spine and the brain was performed at this hospital which showed no abnormality except for the herniation at the level of lumbar L2-L3 with no obvious compression of exiting nerve roots. The problem till then aggravated to the extent that made him quadriplegic and wheelchair bound as well as he started having feeling of being suffocation (**Figure 2a-2e**).



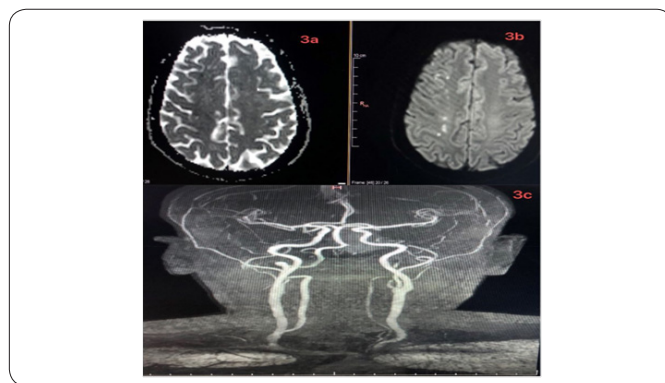
**Figure 2:** (2a) Sagittal MRI of Cervical Spine (Sagittal T2); (2b) Sagittal MRI of dorsal spine (Sagittal T2); (2c) Sagittal MRI of Lumbar spine (Sagittal T2) showing mild protrusion at L3 inter-vertebral disc; (2d) Axial MRI of lumbar spine (axial T2) at L3 space inter-vertebral disc showing no neural compromise; (2e) Axial MRI of Brain (axial T2) showing no significant signal changes or lesions

This was almost 10 days past the first event when he visited ER of our institute. He was diagnosed as hypertension from last 4 years and had well maintained blood pressure with regular intake medicine (losartan 50 mg once a day). He was also taking 0.025mg of levothyroxine since last 1.5 years and maintain well otherwise. He was obese in built. At the presentation in ER, his saturation was fluctuating as low as 85% which had maintained with oxygen supplementation at 2L per min via nasal prongs. His chest was clear with no added sounds. His conscious level was well maintained and no remarkable deficit neurologically except for the power. The power in all limbs was 1/5 and the grip was low as well 2/5 in Medical Research Scale Council (MRC) scale. All the deep tendon reflexes were absent. He was suspected as GuillainBarre Syndrome (GBS) and all the baseline investigations were sent. The lumbar puncture was done and clear cerebrospinal fluid (CSF) was drained which showed classical albumin cytologic dissociation that is protein was more than 3 times higher than the normal range (555mg/dl) while WBC count was nearly at the higher borderline (4/cumm). The other laboratory investigations like MRI of brain and spine and the blood work-up showed no remarkable abnormality, while the rt-PCR for COVID-19 showed positive. He was shifted to the COVID care unit and treated with intravenous immunoglobulin (IVIG) for 5 days and other symptomatic treatment. He completed the course and now is undergoing physiotherapy and rehabilitative program. The COVID status is same and his rt-PCR in the second round is still positive. However, the oxygen saturation and other vitals are stable at present.

### Case 3

A 57-year-old gentle man had experienced mild flu like symptom of mild generalized body pain and the following day he started experiencing tingling sensation in left half of the body. Later several hours apart he

noticed comparative weakness of the left half of the body. The weakness recovered itself as soon as he reached the local health clinic. He had apparently no symptom by that time. He was advised for the neurological evaluation, but the patient chose to return to his home. Later, several hours apart, he experienced another bout weakness and this time it was associated with the slurring of speech. He later visited ER. Upon arrival, the patient received the neurological examination, and he was found to have obvious slurring of speech while there was no facial deviation but mild weakness of the left side of the upper and lower limb (drifts but does not touch the bed). The NIHSS score was 6. He had appeared within the time frame of thrombolysis (3 hrs). He underwent MRI in Stroke protocol (that included MR angiogram and MRI Brain). The MRI showed the showering kind of infarction in the right cerebral hemisphere with mismatch in diffusion weighted imaging (DWI) and apparent diffusion coefficient (ADC) (**Figure 3a**).



**Figure 3:** (3a) Addition diffusion co-efficient (ADC) of MRI of Brain showing signal change in right parietal area corresponding to the diffusion restriction (DWI); (3b) Diffusion weighted imaging (DWI) of brain showing hyper intense signal in right parietal area with ADC match suggesting acute stroke; (3c) MR-Angiogram (MRA) from arch of aorta to circle of Willis showing no significant occlusion or stenosis.

MR angiogram from the arch of aorta till circle of Willis showed no large arterial occlusion but there was seen left hypo plastic vertebral artery (Figure 3b). The other laboratory tests showed no remarkable abnormality. The lipid profile was within normal limits. The random sugar test was also within the normal limit. However, the HbA1C was in higher level (7.2%). The rt-PCR test for COVID-19 came positive. He was shifted for the COVID care unit after thrombolysis. He did not show any respiratory distress or other untoward symptoms. He did well with neurological status and the weakness completely resolved and speech improved as well with much less dysarthria than previous and is vitally stable. Sugar monitoring was also within desired range.

### Discussion

Although it has been several months elapsed since SARS-CoV-2 virus has engulfed the whole world, yet many new clinical features have been observed in COVID patients. The SARS-CoV-2 virus responsible for COVID-19 infection is structural similarity with SARS-CoV-1 virus that was responsible for the SARS pandemic back during 2003. Both viruses use spike proteins on the surface to bind to angiotensin-converting enzyme2 (ACE2) receptor and type 2 trans membrane serine protease (TMPRSS2) on mammalian cells[7]. This implies that the identification

of expression of these receptors in human tissue can predict the potential infected cells and their influences in COVID-19 infected patients. Widespread ACE2 expression in brain explains the cause of neurological disorder in COVID-19 patients [8].

Among neurological disorders, seizure has been seen comparatively commonly. One large cohort study from China had found that out of 304 COVID-19 patients, none exhibited overt seizure and they concluded that this virus did not carry an increased risk of seizure [9]. However, several papers published following months have shown the increased incidence of seizure in COVID-19 patients. The systemic infection itself may perform as a trigger for the breakthrough seizures in the patient with the history of epilepsy or may be the cause of seizure occurrence [10]. A retrospective analysis of case series of 7 cases recently showed that the patients either had new onset of seizure (4 patients) or recurrence of seizure with a history of long duration of well controlled epilepsy (3 patients) [11]. The previous ribonucleic acid (RNA) virus infection (resembling with COVID) pandemic also had shown the increase in incidence of new onset seizure or breakthrough seizures [12]. In our patient (Case 1), he presented with the new onset of seizure with no prior history as such. We believe that the high-grade fever and the low oxygen saturation and respiratory distress due to COVID-19 might have triggered the seizure onset. His EEG was abnormal revealing interictal seizure pattern.

Acute flaccid paralysis is another neurological disorder that has been observed in COVID patients in several countries. The first report of GBS with COVID-19 infection was reported from China [13]. Later, there have been several case reports, case series reported from different places that have been affected by COVID-19 pandemic [5, 14, 15]. In Nepal, however, we had not experienced and believe this is the first case (Case 2). The lower number of cases with the neurological disorder could be because Nepal is seeing the rise in case only recently. Our patient also developed the weakness along with the respiratory distress in about two weeks like the others reported [14, 16, 17]. The diagnosis of GBS is mostly clinical. The ascending type of paralysis, low to absent tendon reflexes strongly suggest GBS. In lab examination, CSF typically shows albumin-cytological dissociation (normal leucocytes and high protein). Nerve Conduction Test (NCT) can also be useful for the diagnosis. Our patient also showed all these features and hence he was easily diagnosed as GBS. He was treated with IVIG and has shown arrest of GBS progression. Several centres have used IVIG in COVID-19 associated GBS cases as well. The pathogenesis of GBS could be due to the immune mediated mechanism (molecular mimicry) in COVID-19 patients that is to say, the infecting SARS-CoV-2 virus likely shares epitopes similar to the peripheral nerves and thereby stimulating autoreactive T or B cells. The antibodies that are produced by the immune system to fight off the COVID-19, cross reacts and binds to the components of the peripheral nervous system, causing the neuronal dysfunction leading to the paralysis.

Cerebrovascular disorder in COVID is another frequently reported case. Nearly 5% of a hospitalized patient in Wuhan (where COVID infection first started) reported acute stroke [5]. Some studies reported that older patients had higher stroke incidence rate while more recent studies reported stroke in younger adults who were infected with COVID-19 [18]. Embolic strokes and large artery strokes have been

reported more often. A retrospective chart review from March 1 till May 1 at two comprehensive stroke centres in US showed that common was stroke (85%) in neurological disorder among the COVID cases. The most common stroke etiology in that cohort was large vessel disease (46%) [19]. Similarly, case reports from other different countries showed that thrombotic complication as arterial clots was observed in COVID-19 infected patients and strokes secondary to the large vessel occlusion [21-22]. There are few popular hypotheses of stroke in COVID-19 infected patients. Endothelial dysfunction because of the virus binding to the ACE2 receptors that are found in the endothelia of cerebral vessels and causing disruption of autoregulatory function [23, 24]. The other is coagulopathy caused by the viral infection leading to sepsis with subsequent appearance in disbalance of coagulation and thereby shedding small emboli causing stroke [22, 25]. Our case (Case 3) also showed embolic type of infarction. The DWI with ADC mismatch confirmed the showering type of infarction. The two-dimensional surface echocardiography (2D-ECHO) did not show any intramural thrombosis or valvular abnormality in cardiac while MR angiogram performed from the arch of aorta (extra cranial) till circle of Willis (intracranial) showed no major vessel occlusion. The cause of stroke in our patient could be due to the septic thrombi.

#### Conclusion

Considering expression of receptors (ACE2/ TMPRSS2) on various organs in human body, COVID-19 can present with any bizarre, typical atypical symptoms. Hence, it is imperative that regardless of etiology, COVID-19 should be considered in the differential diagnosis for patients.

Presenting with neurological disorder during the pandemic. Early consideration of COVID-19 thus may lead to earlier detection and appropriate precautions. Further neuropathological studies and clinical studies on bench side to bed side will be crucial to understanding the pathogenesis of the disease in the central nervous system. Longitudinal neurological assessment of individuals even after recovery from COVID-19 will be crucial to understand the natural history of COVID-19 in the central nervous system and monitor for any long-term neurologic sequel.

#### References

1. Emery SL, Erdman DD, Bowen MD, Newton BR, Winchell JM, et al. "Real-time reverse transcription-polymerase chain reaction assay for SARS-associated coronavirus". *Emerg Infect Dis* 10(2004): 311-316.
2. Guan WJ, Ni ZY, Hu Y, Liang WH, Ou CQ, et al. "Clinical Characteristics of Coronavirus Disease 2019 in China". *N Engl J Med* 382(2020): 1708-1720.
3. Perez CA. "Looking ahead: The risk of neurologic complications due to COVID-19". *Neurol Clin Pract* 10(2020): 371-374.
4. Zubair AS, McAlpine LS, Gardin T, Farhadian S, Kuruvilla DE, et al. "Neuropathogenesis and Neurologic Manifestations of the Coronaviruses in the Age of Coronavirus Disease 2019: A Review". *JAMA Neurology* 77(2020): 1018-1027.
5. Mao L, Jin H, Wang M, Hu Y, Chen S, et al. "Neurologic Manifestations of Hospitalized Patients With Coronavirus Disease 2019 in Wuhan, China". *JAMA Neurol* 77(2020): 683-690.
6. Ghannam M, Alshaer Q, Al-Chalabi M, Zakarna L, Robertson J, et al. "Neurological involvement of coronavirus disease 2019: A systematic review". *J Neurol* 267(2020): 3135-3153.

7. Hoffmann M, Kleine-Weber H, Schroeder S, Kruger N, Herrler T, et al. "SARS-CoV-2 Cell Entry Depends on ACE2 and TMPRSS2 and Is Blocked by a Clinically Proven Protease Inhibitor". *Cell* 181(2020):271-280.
8. Doobay MF, Talman LS, Obr TD, Tian X, Davisson RL, et al. "Differential expression of neuronal ACE2 in transgenic mice with overexpression of the brain renin-angiotensin system". *Am J Physiol Regul Integr Comp Physiol* 292(2007):373-381.
9. Lu L, Xiong W, Liu D, Liu J, Yang D, et al. "New onset acute symptomatic seizure and risk factors in coronavirus disease 2019: A retrospective multicenter study". *Epilepsia* 61(2020): 49-53.
10. Rana A, Musto AE. "The role of inflammation in the development of epilepsy". *J Neuroinflammation* 15(2018):144.
11. Anand P, Al-Faraj A, Sader E, Dashkoff J, Abdennadher M, et al. "Seizure as the presenting symptom of COVID-19: A retrospective case series". *Epilepsy Behav* 112(2020):107335.
12. Asadi-Pooya AA. "Seizures associated with coronavirus infections". *Seizure* 79(2020) :49-52.
13. Zhao H, Shen D, Zhou H, Liu J, Chen S. Guillain-Barre syndrome associated with SARS-CoV-2 infection: causality or coincidence?. *Lancet Neurol* 19(2020):383-384.
14. Toscano G, Palmerini F, Ravaglia S, Ruiz L, Invernizzi P, et al. "Guillain-Barre Syndrome Associated with SARS-CoV-2". *N Engl J Med* 382(2020):2574-2576.
15. El Otmani H, El Moutawakil B, Rafai MA, El Benna N, El Kettani C, et al. "Covid-19 and Guillain-Barre syndrome: More than a coincidence". *Rev Neurol (Paris)* 176(2020):518-519.
16. Caress JB, Castoro RJ, Simmons Z, Scelsa SN, Lewis RA, et al. "COVID-19-associated Guillain-Barre syndrome: The early pandemic experience". *Muscle Nerve* 62(2020):485-491.
17. Virani A, Rabold E, Hanson T, Haag A, Elrufay R, et al. "Guillain-Barre Syndrome associated with SARS-CoV-2 infection". *IDCases* 20(2020): 00771.
18. Oxley TJ, Mocco J, Majidi S, Kellner CP, Shoirah H, et al. "Large-Vessel Stroke as a Presenting Feature of Covid-19 in the Young". *N Engl J Med* 382(2020):60.
19. Reddy ST, Garg T, Shah C, Nascimento FA, Imran R, et al. "Cerebrovascular Disease in Patients with COVID-19: A Review of the Literature and Case Series". *Case Rep Neurol* 12(2020):199-209.
20. Klok FA, Kruip M, van der Meer NJM, Arbous MS, Gommers D, et al. "Incidence of thrombotic complications in critically ill ICU patients with COVID-19". *Thromb Res* 191(2020):145-147.
21. Beyrouti R, Adams ME, Benjamin L, Cohen H, Farmer SF, et al. "Characteristics of ischaemic stroke associated with COVID-19". *J Neurol Neurosurg Psychiatry* 91(2020):889-891.
22. Saavedra JM. "Brain angiotensin II: new developments, unanswered questions and therapeutic opportunities". *Cell Mol Neurobiol* 25(2005):485-512.
23. Al Saiegh F, Ghosh R, Leibold A, Avery MB, Schmidt RF, et al. "Status of SARS-CoV-2 in cerebrospinal fluid of patients with COVID-19 and stroke". *J Neurol Neurosurg Psychiatry* (2020):846-848.
24. Sharifi-Razavi A, Karimi N, Rouhani N. "COVID-19 and intracerebral haemorrhage: causative or coincidental?". *New Microbes New Infect* 35(2020):100669.
25. Han H, Yang L, Liu R, Liu F, Wu KL, et al. "Prominent changes in blood coagulation of patients with SARS-CoV-2 infection". *Clin Chem Lab Med* 58(2020) :1116-1120.

**Citation:** Chandra A, Thapa S, Chandra A, Jha A, Giri S, et al. "Neurological Manifestations Presenting in COVID 19: A Case Series from Nepal." *J Clin Case Stud Rev* (2020): 1; 001-005