

See discussions, stats, and author profiles for this publication at: <https://www.researchgate.net/publication/354752690>

# A case report of multiple isolated intradural neurocysticercosis of the lumbosacral spine

Article in *International Journal of Surgery Case Reports* · September 2021

DOI: 10.1016/j.ijscr.2021.106434

CITATIONS

0

READS

70

6 authors, including:



**Suyasha Rajbhandari**

Annapurna Neurological Institute & Allied Sciences

5 PUBLICATIONS 3 CITATIONS

[SEE PROFILE](#)



**Pritam Gurung**

Annapurna Neurological Institute & Allied Sciences

36 PUBLICATIONS 40 CITATIONS

[SEE PROFILE](#)



**Jayant Yadav**

Institute of Medicine

39 PUBLICATIONS 292 CITATIONS

[SEE PROFILE](#)



**Pravesh Rajbhandari**

Annapurna Neurological Institute & Allied Sciences

53 PUBLICATIONS 91 CITATIONS

[SEE PROFILE](#)

Some of the authors of this publication are also working on these related projects:



Acute stroke [View project](#)



Case report [View project](#)



## Case report

## A case report of multiple isolated intradural neurocysticercosis of the lumbo-sacral spine

Suyasha Rajbhandari<sup>\*</sup>, Pritam Gurung, Jayant Yadav, Pravesh Rajbhandari, Samir Acharya, Basant Pant

Annapurna Neurological Institute and Allied Sciences, Nepal

## ARTICLE INFO

## Keywords:

Intraspinal  
Neurocysticercosis  
Isolated  
Intradural  
Case report

## ABSTRACT

**Introduction and importance:** Neurocysticercosis is the most common parasitic infection of the nervous system and it is mostly intracranial. Intradural intramedullary or extramedullary is the rarest involvement of intraspinal cysticercosis. Its isolated involvement is even rare, as it usually has intracranial association.

We aim to report a rare case of isolated intraspinal neurocysticercosis and discuss the measures we can take for early management. Despite being an eradicable disease of public health importance, its prevalence is increasing widely in developed countries too. Therefore, we aim to discuss its pathogenesis, mode of spread, and preventive aspects as well.

**Presentation of case:** A 40-year-old woman presented to our hospital with pain over the lower back region radiating to the right thigh. Magnetic Resonance Imaging (MRI) of her lumbosacral spine revealed a cystic lesion at the spinal level L5-S1. We confirmed the diagnosis via Histopathological examination (HPE) following surgery. **Discussion:** Isolated intradural neurocysticercosis of the spine is extraordinarily rare involvement. It is caused by the larval stage of taenia solium. An MRI is the preferred imaging modality. Due to rarity and nonspecific clinic-radiological findings, diagnosis may often be missed. In our case, MRI revealed a cystic lesion at the L5-S1 level of the spine and multiple cystic lesions at the level were found intra-operatively. Its diagnosis is confirmed by HPE. Treatment can be medical or surgical according to the severity of the disease.

**Conclusion:** Although rare, neurocysticercosis can cause irreversible neurological damage. Therefore, surgeons should consider it in the differential diagnosis of intraspinal lesions.

## 1. Introduction

Neurocysticercosis is the most common parasitic infection of the nervous system [1], caused by the larval stage of taenia solium [2]. It is the most common cause of acquired epilepsy [1,2]. The disease is endemic in low economy countries like Nepal due to a lack of awareness about hygiene and poor sanitation provisions [2]. It is highly endemic in Latin America, sub-Saharan Africa, and parts of Asia [3]. The prevalence of this disease in Nepal ranges from 0.002 to 0.1% [2].

Neurocysticercosis is most commonly intracranial, and involvement of the spinal cord is very unusual even in the endemic areas and occurs in just 0.7 to 5.85% of cases [4]. Spinal cysticercosis is most commonly associated with primary intracranial lesions [5]. It usually involves the thoracic level [1] and mainly affects the subarachnoid space [6].

Anatomically, spinal cysticercosis can be classified as extraspinal or intraspinal (Epidural, subdural, arachnoid, or intramedullary) [7]. Intradural extramedullary or intramedullary involvement of the spine is the rarest variant [8]. Its mass effect can have grave consequences due to the limited area of the spinal canal [9], and therefore early diagnosis and treatment are crucial.

Herein, we report an unusual case of multiple isolated intradural neurocysticercosis at the spinal level L5-S1. Preoperatively, neurocysticercosis was not considered a differential diagnosis. The diagnosis was confirmed after surgery by histopathological examination (HPE). The work has been reported in line with the SCARE 2020 criteria [10].

**Abbreviations:** BMI, body mass index; CSF, cerebrospinal fluid; EITB, enzyme-linked immune electro transfer blot assay; HPE, histopathological examination; MRI, magnetic resonance imaging.

<sup>\*</sup> Corresponding author at: Annapurna Neurological Institute and Allied Sciences, 44600 Kathmandu, Nepal.

E-mail addresses: [suyasharajbhandari1882@gmail.com](mailto:suyasharajbhandari1882@gmail.com) (S. Rajbhandari), [jkyadav22@iom.edu.np](mailto:jkyadav22@iom.edu.np) (J. Yadav).

<https://doi.org/10.1016/j.ijscr.2021.106434>

Received 15 August 2021; Received in revised form 17 September 2021; Accepted 17 September 2021

Available online 22 September 2021

2210-2612/© 2021 The Authors. Published by Elsevier Ltd on behalf of IJS Publishing Group Ltd. This is an open access article under the CC BY-NC-ND license

(<http://creativecommons.org/licenses/by-nc-nd/4.0/>).

## 2. Case presentation

A 40-year-old woman with a BMI (Body Mass Index) of 21 kg/m<sup>2</sup> presented to Annapurna Neurological Institute and Allied Sciences, Kathmandu, Nepal, in the out-patient department with a complaint of pain over the lower back region radiating to the right thigh for two years which was gradually progressive. She also complained of associated numbness and tingling sensation progressing towards the right lower limb. Her past medical history, family history and social history were unremarkable. General physical examination revealed no abnormality. The patient exhibited intact neurological and systemic examination findings.

Magnetic resonance imaging (MRI) of the lumbosacral spine revealed well defined T2 hyperintense signal lesion extending from the lower level of L5 up to mid of S1 vertebral body, predominantly involving right L5-S1 lateral recess and causing right L5-S1 lateral recess stenosis with compression on the right S1 traversing nerve root (Fig. 1a, b) and two small well defined T2 hyperintense signal foci at S1 vertebral level measuring 0.4 cm × 0.7 cm and 0.6 cm × 0.5 cm respectively. Other investigations did not reveal any abnormality. Cerebrospinal fluid (CSF) and serological examinations were not done.

The patient underwent a right L5-S1 laminectomy and removal of the cysts. Intraoperatively, after the dural opening, we found multiple cystic lesions having yellowish walls at the L5-S1 level of the spine with gross adhesion around the spinal nerves. The HPE examination confirmed intraspinal neurocysticercosis (Fig. 2).

The postoperative period was uneventful, and she was given anti-inflammatory medication (corticosteroids: dexamethasone 4 mg in tapering dose) following the surgery. We discharged the patient on the 6th postoperative day. At discharge, her preoperative symptoms like numbness and tingling sensation had improved. However, on follow-up after a month, she still complained of pain over the lower back radiating to the right thigh, and we started her on albendazole therapy (200 mg QID for 21 days). During her follow-up, one year after the surgery and postoperative medication, an MRI was repeated, which was unremarkable (Fig. 3a, b). According to the patient, her symptoms had significantly improved, she had near normal functional capacity with occasional lower back pain.

## 3. Discussion

Neurocysticercosis is a major public health problem in Nepal and its prevalence is increasing in developed countries due to migration and

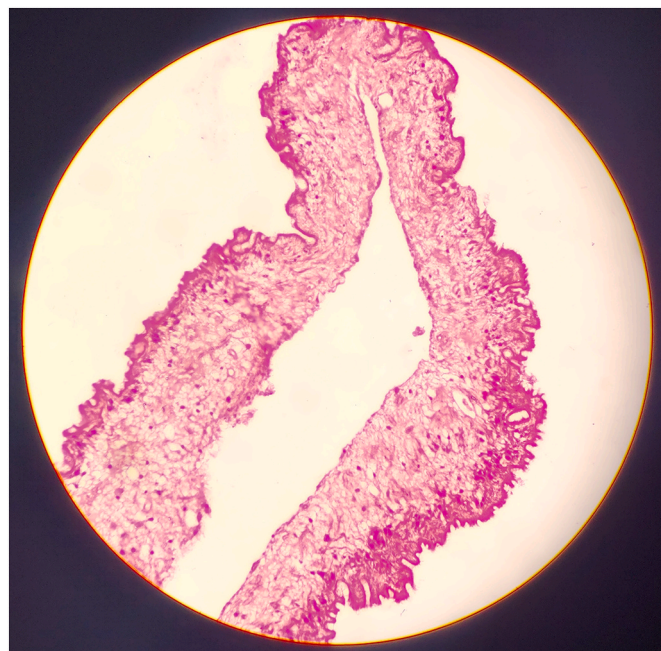


Fig. 2. Hematoxylin and eosin stain showing outer cuticular layer, middle nuclear layer, and inner reticular layer of cyst wall.

globalization [2]. The disease is transmitted after ingestion of any uncooked food contaminated with feces [2]. Adult tapeworm matures in the small intestine of humans and releases gravid proglottids/eggs that are passed in the feces and consumed by the intermediate host (pigs), these eggs reside in the organs and muscles of the pig as cysticerci [2]. Disease transmission occurs by undercooked consumption of this meat containing cysticerci [2]. Furthermore, humans themselves can act as an intermediate host and develop cysticercosis by consuming uncooked food contaminated with eggs [8].

There are four pathological stages of intraspinal neurocysticercosis (vesicular, colloidal vesicular, granular nodular, and nodular calcified) [6]. Clinical manifestations during the vesicular stage (active form) are due to mass effects that include quadriparesis, paraparesis, sensory loss, autonomic dysfunction, radicular pain [4]. Local inflammation may occur against cysticercal antigens released when the cyst degenerates, which may manifest as myelitis, radiculitis, and local meningitis [4].

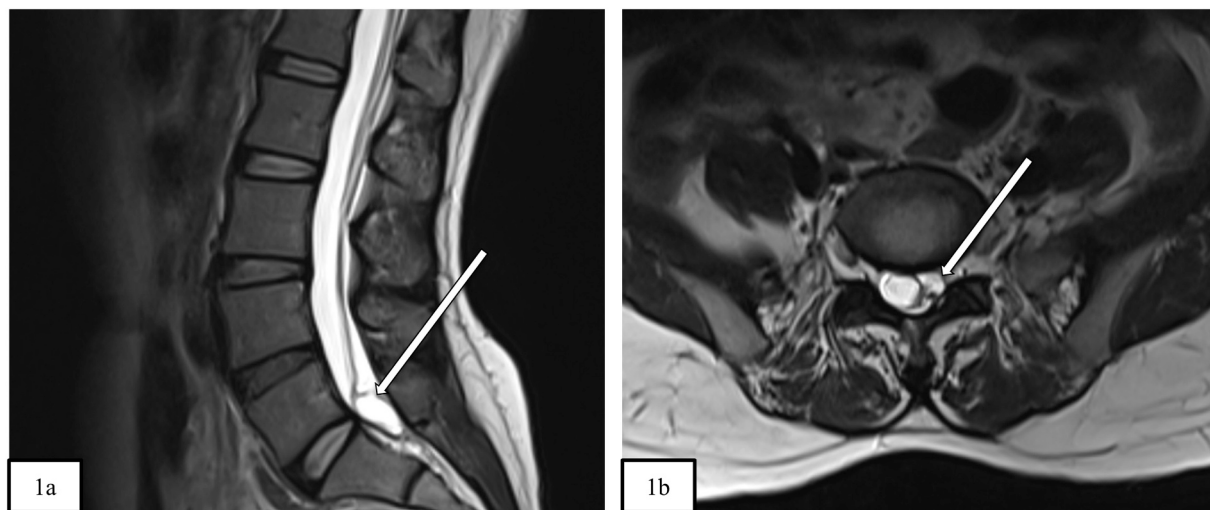
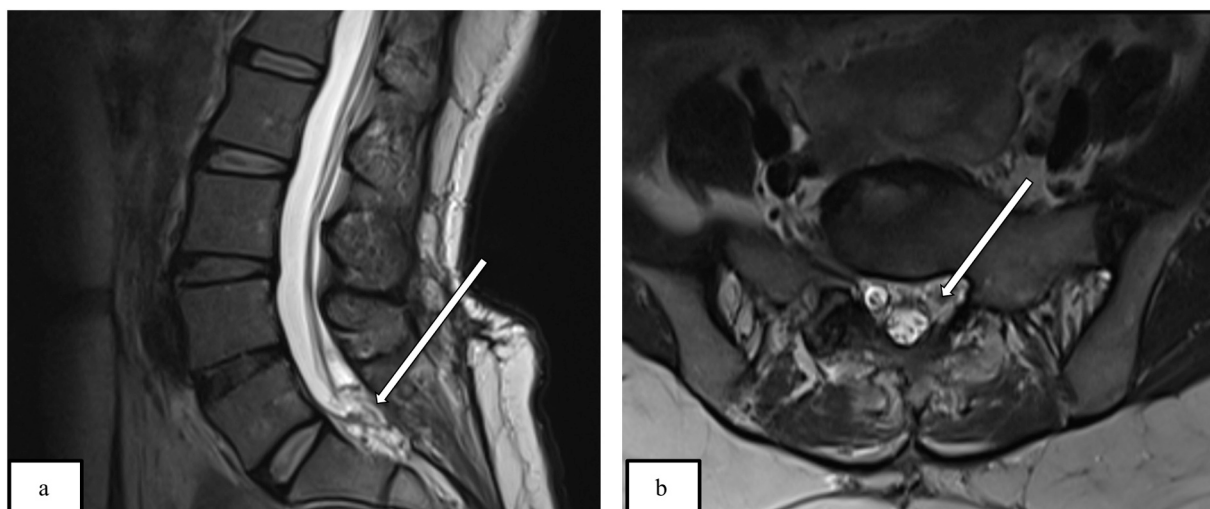


Fig. 1. Lumbo-sacral spinal magnetic resonance imaging. a) Sagittal T2 weighted image showing well defined hyperintense signal lesion measuring about 0.9 cm × 1.2 cm × 2.0 cm (AP × W × H) extending from the lower level of L5 up to S1 vertebral body. (b) Axial T2 weighted image showing intradural location of the lesion.



**Fig. 3.** Lumbo-sacral spinal magnetic resonance imaging. a.) Postoperative sagittal T2 weighted image showing removal of the lesion at the lumbosacral spine. (b.) Postoperative axial T2 weighted image showing removal of the lesion at the lumbosacral spine.

Clinical presentation of intraspinal neurocysticercosis varies according to the location of lesions within the spinal cord, number, size of cysts, and presence or absence of local inflammation [1]. The differential diagnosis includes arachnoid cyst, ependymal cyst, neurenteric cyst, sarcoidosis, and neoplasms [7]. There is no pathognomonic feature of this disease [6].

The unique findings in our case are as follows 1.) The patient had indistinguishable and vague clinical features, no previous history of parasitic infection, and no association with cerebral neurocysticercosis. 2.) The isolated primary involvement of neurocysticercosis is very unusual. As per a 2017 article, less than 200 cases of primary spinal cysticercosis had been reported till that date [11]. 3.) Spinal cysticercosis mostly involves the thoracic level [1] while in our case it involved the lumbosacral spine. 4.) Spinal cysticercosis mimicked a perineural cyst in an MRI scan, which led to an initial misdiagnosis. Clinical suspicion of spinal cysticercosis was difficult and CSF examination was not performed. Surgical excision revealed multiple cysts which HPE confirmed as neurocysticercosis.

It is supposed that cysticerci tend to reside in areas where there is high blood flow (brain, eyes, muscles) [2,9]. Additionally, high glycogen or glucose content in these tissues favor their inhabitation [2]. The intraspinal lesion is presumed to occur as a result of the direct hematogenous spread of eggs to the spinal cord [9]. Isolated intramedullary involvement is very rare due to the inability of cysticerci to disseminate into the spinal subarachnoid space [4]. It is also presumed that isolated spinal involvement may occur due to direct dissemination as drop lesions through cerebrospinal fluid or retrograde migration of cysticerci through the epidural venous plexus [5].

Diagnosis of intraspinal cysticercosis is confirmed through HPE [4,7]. Precise information and location are provided by an MRI [6], the lesion appears hypointense in T1 weighted images and hyperintense in T2 weighted images [1,8]. CSF studies show evidence of inflammation that includes lymphocytic pleocytosis, variable eosinophilic pleocytosis, raised proteins, and normal to low glucose levels [7]. In terms of serologic testing, CSF and serum enzyme-linked immune electro transfer blot assay (EITB) or enzyme-linked immunosorbent assay can be remarkable, of which EITB is more specific [3,9].

Treatment of intraspinal neurocysticercosis is usually either medical or surgical [1]. The most preferred medicine for this condition is albendazole and is considered for patients who have stable neurological status [9]. Although treatment regimens are not standardized, the use of corticosteroids (dexamethasone-0.2 mg/kg/day) along with the anti-parasitic medication (albendazole- 15 mg/kg/day) is recommended in

all patients showing signs of cord dysfunction [3]. The duration of therapy is to be individualized, according to the response to treatment [3]. The corticosteroids doses are tapered and close follow-up of the patient is essential [3]. In cases presenting with acute symptoms, progressive neurological deterioration despite corticosteroids, or when the diagnosis is in doubt, surgical intervention is considered [3]. Surgery facilitates both eradication of lesions and confirmation of diagnosis after the HPE [4]. Because its transmission is due to poor sanitary practices, better public health policies will help to prevent the spread of disease and its complete eradication.

#### 4. Conclusion

The isolated form of intraspinal neurocysticercosis is very rare, as it is usually associated with intracranial lesions. The presented case is unusual as there was an isolated involvement of cysticercosis in the spine with no primary brain involvement. As low suspicion may lead to unnecessary investigations, and delay in diagnosis leading to grave complications, it is imperative to consider cysticercosis in the differential diagnosis of intraspinal lesions both in developing and developed areas.

#### Sources of funding

No source of funding for the publication of this article.

#### Ethical approval

The case study was cleared by the institutional review committee of Annapurna Neurological Institute and Allied Sciences.

#### Consent for publication

Written informed consent was obtained from the patient for publication of this case report and accompanying images. A copy of the written consent is available for review by the Editor-in-Chief of this journal on request.

#### Provenance and peer review

Not commissioned, externally peer-reviewed.

**Research registration**

Not applicable.

**Guarantor**

Dr. Suyasha Rajbhandari.

**Author contribution**

Suyasha Rajbhandari: Writing- Original draft, Conceptualization, review and editing.

Pritam Gurung: Review, editing and supervision.

Jayant Yadav: Manuscript reviewer.

Pravesh Rajbhandari: Established the diagnosis and treated the patient.

Samir Acharya: Established the diagnosis and treated the patient.

Basant Pant: Supervision.

**Declaration of competing interest**

None of the authors have potential conflicts of interest to be disclosed.

**Acknowledgement**

None.

**References**

- [1] S. Ganesan, S. Acharya, K.L. Kalra, R. Chahal, Intradural neurocysticercosis of lumbar spine: a case report, *Glob. Spine J.* 5 (2015) 1–4, <https://doi.org/10.1055/s-0034-1394125>.
- [2] B. Joshi, The epidemiology and health burden of neurocysticercosis in Nepal, *Int. J. Trop. Dis. Heal.* 4 (2014) 204–223, <https://doi.org/10.9734/ijtdh/2014/5029>.
- [3] A.C. White C.M. Coyle V. Rajshekhar et al Clinical Infectious Diseases, (n.d.). doi: 10.1093/cid/cix1084.
- [4] Z. Qazi, B.K. Ojha, A. Chandra, S.K. Singh, C. Srivastava, T.B. Patil, Isolated intramedullary spinal cord cysticercosis, *J. Neurosci. Rural Pract.* 5 (2014) S66–S68, <https://doi.org/10.4103/0976-3147.145209>.
- [5] S. Lopez, F. Santillan, J.J. Diaz, P. Mogrovejo, Spinal cord compression by multiple cysticercosis, *Surg. Neurol. Int.* 10 (2019) 94, <https://doi.org/10.25259/sni-46-2019>.
- [6] I. Pant, S. Chaturvedi, G. Singh, S. Gupta, R. Kumari, Spinal cysticercosis: a report of two cases with review of literature, *J. Craniovertebr. Junction Spine.* 7 (2016) 286, <https://doi.org/10.4103/0974-8237.193261>.
- [7] M. Kim, S.C. Rhim, S.-K. Khang, Intramedullary spinal cysticercosis: a case report and review of literature, *Korean J. Spine.* 11 (2014) 81, <https://doi.org/10.14245/kjs.2014.11.2.81>.
- [8] S. Zhang, Y. Hu, Z. Li, L. Zhao, Z. Wang, Lumbar spinal intradural neurocysticercosis: a case report, *Exp. Ther. Med.* 13 (2017) 3591–3593, <https://doi.org/10.3892/etm.2017.4403>.
- [9] P. Maste, Y. Lokanath, S. Mahantshetti, S. Soumya, Isolated intramedullary spinal cysticercosis: a case report with review of literature of a rare presentation, *Asian J. Neurosurg.* 13 (2018) 154, <https://doi.org/10.4103/1793-5482.180894>.
- [10] for the SCARE Group, R.A. Agha, T. Franchi, C. Sohrabi, G. Mathew, The SCARE 2020 guideline: updating consensus Surgical CAse REport (SCARE) guidelines, *Int. J. Surg.* 84 (2020) 226–230, <https://doi.org/10.1016/J.IJSU.2020.10.034>.
- [11] A. Pal, C. Biswas, T.R. Ghosh, P. Deb, A rare case of recurrence of primary spinal neurocysticercosis mimicking an arachnoid cyst, *Asian J. Neurosurg.* 12 (2017) 250, <https://doi.org/10.4103/1793-5482.144176>.