

See discussions, stats, and author profiles for this publication at: <https://www.researchgate.net/publication/349604344>

# 68 Case Report To access Nepal Journal of Neuroscience Archives, scan QR code: A Case Report of Lhermitte- Duclos Disease in a 10- Month-Old Child Presenting with Hydrocephalus

Article in *Nepal Journal of Neuroscience* · January 2019

DOI: 10.3126/njn.v19i3.27363

CITATIONS

0

READS

11

7 authors, including:



**Samir Acharya**

Annapurna Neurological Institute & Allied Sciences

35 PUBLICATIONS 33 CITATIONS

[SEE PROFILE](#)



**Pravesh Rajbhandari**

Annapurna Neurological Institute & Allied Sciences

53 PUBLICATIONS 91 CITATIONS

[SEE PROFILE](#)



**Basant Pant**

Annapurna Neurological Institute & Allied Sciences

134 PUBLICATIONS 809 CITATIONS

[SEE PROFILE](#)



**Abhishek Tamrakar**

Annapurna Neurological Institute & Allied Sciences

3 PUBLICATIONS 0 CITATIONS

[SEE PROFILE](#)

Some of the authors of this publication are also working on these related projects:



Case report [View project](#)



Aneurysm management during covid era [View project](#)

**Dr. Abhishek Tamrakar MBBS**

Department of Neurosurgery  
Annapurna Neurological Institute and Allied Sciences  
Maitighar, Kathmandu, Nepal  
ORCID iD: <https://orcid.org/0000-0001-6806-0243>

**Dr. Pritam Gurung MD, Ph.D.**

Department of Neurosurgery  
Annapurna Neurological Institute and Allied Sciences  
Maitighar, Kathmandu, Nepal  
ORCID iD: <https://orcid.org/0000-0003-2571-7270>

**Dr. Samir Acharya MS**

Department of Neurosurgery  
Annapurna Neurological Institute and Allied Sciences  
Maitighar, Kathmandu, Nepal  
ORCID iD: <https://orcid.org/0000-0003-1223-1562>

**Dr. Pravesh Rajbhandhari MS**

Department of Neurosurgery  
Annapurna Neurological Institute and Allied Sciences  
Maitighar, Kathmandu, Nepal  
ORCID iD: <https://orcid.org/0000-0001-6093-5850>

**Dr. Basant Pant MD, Ph.D.**

Department of Neurosurgery  
Annapurna Neurological Institute and Allied Sciences  
Maitighar, Kathmandu, Nepal  
ORCID iD: <https://orcid.org/0000-0003-1424-907X>

**Address for correspondence:**

Dr. Abhishek Tamrakar MBBS  
Department of Neurosurgery  
Annapurna Neurological Institute and Allied Sciences  
Maitighar, Kathmandu, Nepal  
E-mail: [docabhishektamrakar@gmail.com](mailto:docabhishektamrakar@gmail.com)  
Contact number: +977 9841777299

**Date of submission:** 18<sup>th</sup> November 2019

**Date of acceptance:** 21<sup>st</sup> December 2019

DOI: <https://doi.org/10.3126/njn.v19i3.27363>

**HOW TO CITE**

Tamrakar A, Gurung P, Acharya S, Rajbhandhari P, Pant B.  
A Case Report of Lhermitte-Duclos Disease in a 10-Month-Old  
Child Presenting with Hydrocephalus. NJNS 2019;19(3):68-71

To access Nepal Journal of Neuroscience Archives,  
scan QR code:



## A Case Report of Lhermitte-Duclos Disease in a 10-Month-Old Child Presenting with Hydrocephalus

Lhermitte–Duclos Disease is a rare entity characterized by diffuse or focal enlargement of cerebellar folia. Clinical manifestations are usually related to a mass effect and secondary obstructive hydrocephalus. Increased intracranial pressure symptoms and cerebellar symptoms are the most frequent patient complaints. We present a 10-month-old male child with his mother who presented to the outpatient department with complaints of enlargement of size of head since the last one week. Magnetic Resonance Imaging scan revealed the features of Lhermitte–Duclos Disease involving the right cerebellar hemisphere with marked post contrast gyral enhancement. He underwent endoscopic third ventriculostomy. Lhermitte–Duclos Disease is very rare in early childhood and should be considered in the differential diagnosis of posterior fossa lesions.

**Key words:** Cerebellar lesion, Dysplastic cerebellar gangliocytoma, Lhermitte–Duclos Disease

A 10-month-old boy with his mother presented to out patient department (OPD) with complaints of enlargement of size of head since the last one week. Patient was born via cesarean section with APGAR of 8, 9. He had no prior episodes of loss of consciousness or any preceding or intercurrent illnesses. He had no prior medical history and met normal developmental milestones. Sunset sign was positive.

On examination, the circumference of head was 45 centimetres (cm). The child seemed drowsy and sunset sign was progressive. Neurological examination revealed no deficits.

Magnetic Resonance Imaging (MRI) of brain showed altered signal intensity involving the whole of the right cerebellar hemisphere showing predominant hypointense signal on T1 (Figure 1a) and hyperintense signal on T2 (Figure 1c) / FLAIR. The involved right cerebellar hemisphere showed widened cerebellar folia with alternating hypo/iso intense signal on T1 and hyper/iso intense signal on T2. This was causing expansion of the right cerebellar hemisphere causing displacement and compression of the foramen of aqueduct and the 4<sup>th</sup> ventricle. There was proximal moderate dilatation of the 3<sup>rd</sup> ventricle and the bilateral lateral ventricles with symmetric marked periventricular ooze. There was associated bony remodelling of the right cerebellar convexity with enlargement of the head. There was slit like appearance of the 4<sup>th</sup> ventricle with flattening of the posterior margin of the brain stem. Cerebellar tonsillar herniation measuring five millimetres below the level of the foramen magnum could be seen. There was surrounding T2/FLAIR hyperintensity involving the right inferior cerebellar peduncle and left dentate nucleus. Rest of the cerebellar hemisphere showed normal sulcal pattern. Post Contrast MRI showed marked gyral enhancement. These features were suggestive of Lhermitte–Duclos Disease (LDD). The patient underwent endoscopic third ventriculostomy.

Postoperative course was uneventful and the patient improved with no neurological deficits. Immediate post-operative scans were not done because of non compliance from child and patient party. He was observed for symptoms of raised intracranial pressure (ICP) which was not significant and was discharged on 3<sup>rd</sup> post operative day. He was asked to follow up in OPD after a month and next after six months.

### Discussion

Lhermitte–Duclos Disease (LDD) is a rare cerebellar lesion, described in 1920 by two French physicians: Lhermitte and Duclos. This entity, also called dysplastic cerebellar gangliocytoma, is characterized by a unique

pattern of cellular disorganization, hypertrophied granular-cell neurons, and axonal hypermyelination in the molecular layer of the cerebellum. The clinical presentation of this disease is not specific, it is usually related to intracranial pressure, cerebellar dysfunction, and cranial nerve deficits, and it is mainly diagnosed by cerebral magnetic resonance imaging (MRI). Lhermitte–Duclos Disease is a rare disease, with no race or sex preferences<sup>1</sup>. It usually affects people between 30 and 50 years of age though it may occur at any age<sup>1</sup>. In our case the patients age is ten months. Only 200 cases have been reported so far. Lhermitte and Duclos described the histopathology of the lesion for the first time, characterized by a loss of granular cells, purkinje cells and white matter, and an overgrowth of cerebellar ganglion cells, which cause the thickening of the cerebellar folia<sup>2</sup>.

LDD may show close relationship with Cowden syndrome, called hamartoma-neoplasia syndrome, which associate multiple hamartomas and a high risk of malignant tumors<sup>3</sup>. Other reported associations include megalencephaly, polydactyly, local gigantism, heteropias, and cutaneous hemangiomas but our patient had an isolated cerebellar mass. Clinically there is minimal chances for LDD patient to have symptoms if any ataxia, headache, cranial nerve palsies etc while intracranial pressure and hydrocephalus is observed in severe cases<sup>4</sup>. Our patient presented with merely the features of raised intracranial pressure.

Histopathological findings include absence of purkinje cell layer, increase in myelination of axons in the molecular layer, hypertrophy in the granular cell layer and atrophy in cerebellar white matter<sup>5</sup>. Association of LDD with chromosomal mutation suggests genetic control of the dysplasia<sup>6,7</sup>. Phosphatase and tensin homolog (PTEN) gene mutation are associated with this genetic disorder. Mutation in this region can promote proliferation and invasion as well as inhibit apoptosis, and the mutated allele has been shown to be expressed in 83% of pathological specimens<sup>6</sup>. Mutation in the PTEN gene has a tendency to produce dysplastic-hyperplastic lesions and neoplasm in the skin, gonads, thyroid, and colon. These kind of mutations are also observed in Cowden disease. Padberg et al postulated that Cowden disease and LDD could be related to each other, and that LDD could be one of the central nervous system manifestations associated with Cowden disease, such as megalencephaly, mental impairment, and seizure<sup>8</sup>.

On computerised tomography scans, LDD can mimic posterior fossa tumor. The typical appearance is that of a poorly delineated hypo or isodense posterior fossa lesion that does not enhance following contrast administration. Mass effect and displacement of the fourth ventricle may

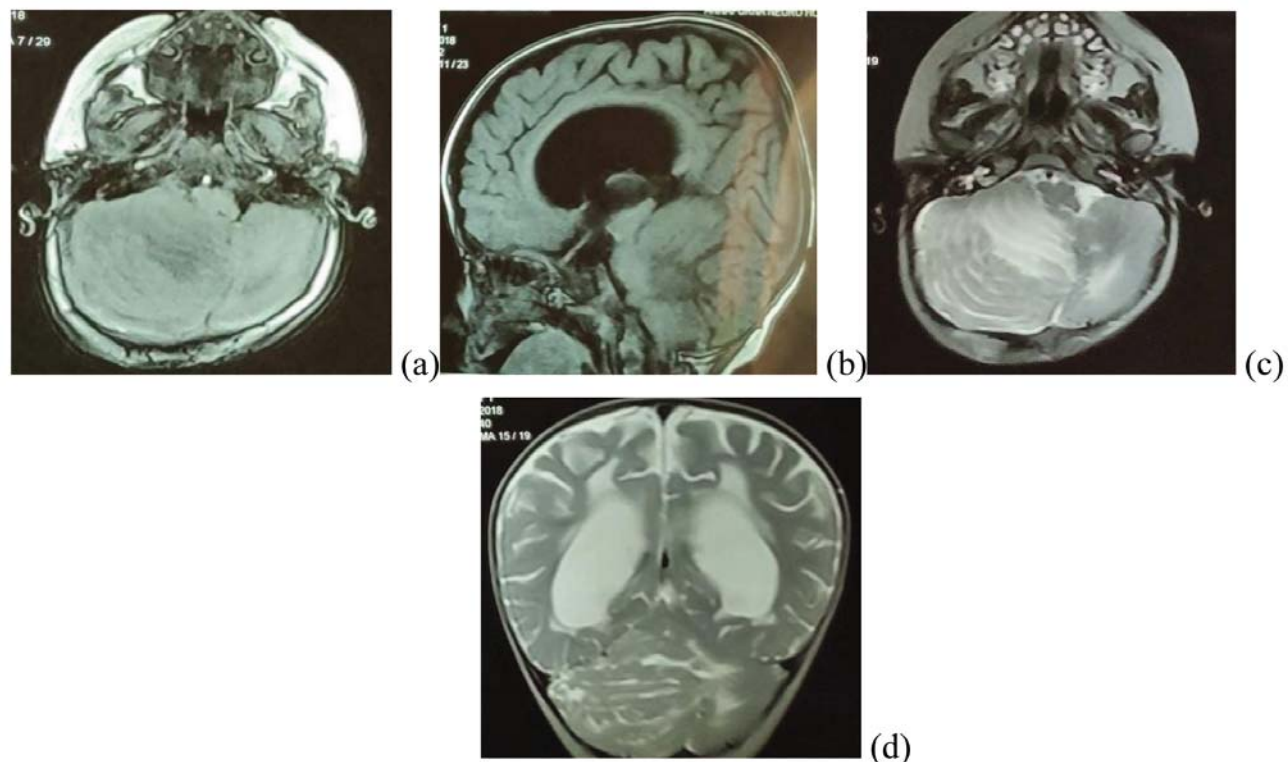


Figure 1: (a)T1-weighted axial, (b)T1-weighted sagittal, (c)T2-weighted axial, (d) T2-weighted coronal MRI brain of the patient showing a right cerebellar mass

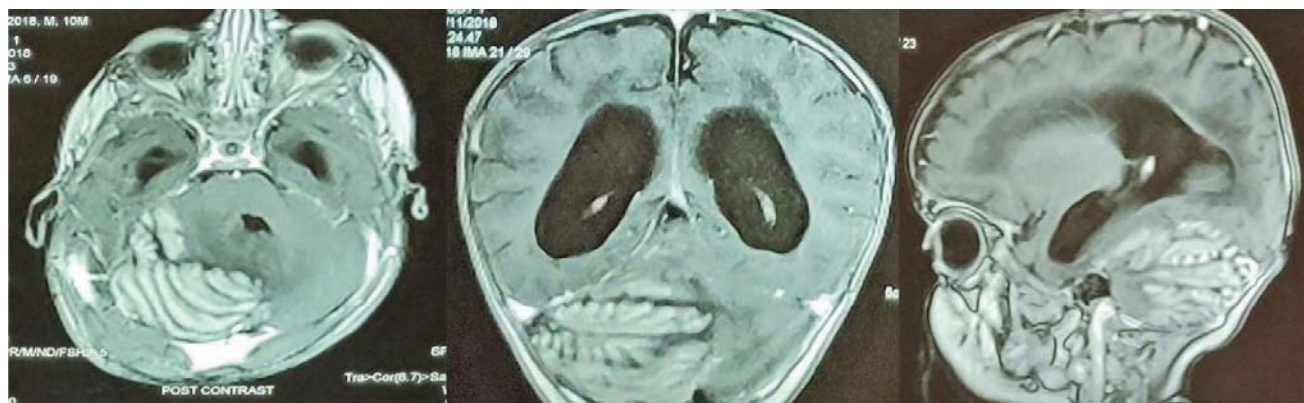


Figure 2: Post Contrast MRI showing marked gyral enhancement

occur. MRI demonstrates a low signal, non enhancement mass on T1-weighted studies. A very characteristic laminated, or folial pattern of increased signal is seen on T2-weighted scans and should suggest the diagnosis. It has characteristic striated appearance (tiger stripes) due to widened cerebellar folia. In our case, the MRI features were similar.

The natural history of LDD is not well known<sup>9</sup>. Definitive treatment of LDD is very controversial. Surgical excision may be considered when there is significant mass

effect. Complete excision of the hypertrophied lesion is the treatment of choice, but total excision destroying important adjacent structures is unnecessary, because of the benign nature of LDD, especially in elderly patients. Zak et al reported an infantile patient with LDD which involved the entire cerebellum and as surgery could not be an option, they started rapamycin therapy<sup>10</sup>. In our case, we have decided to choose Endoscopic Third Ventriculostomy (ETV) as the treatment modality due to hydrocephalus. Efficacy of radiotherapy and chemotherapy is unknown.

### Conclusion

LDD is very rare in early childhood and should be considered in the differential diagnosis of posterior fossa lesions. It can mimic low-grade tumor.

### References

1. Vinchon M, Blond S, Lejeune JP, Krivosik I, Fossati P, Assaker R, et al. Association of Lhermitte-Duclos and Cowden disease: Report of a new case and review of the literature. **J Neurol Neurosurg Psychiatry.** **1994;57(6):**699–704. DOI: 10.1136/jnnp.57.6.699
2. Tan TC, Ho LC. Lhermitte-Duclos disease associated with Cowden syndrome. **J Clin Neurosci.** **2007 Aug;14(8):**801-5. DOI: 10.1016/j.jocn.2006.06.007
3. Barone F, Noubari BA, Torrisi A, Lanzafame S, Tropea R, Mancuso P. Lhermitte duclos disease and Cowden disease: clinical, pathological and neuroimaging study of a case. **J Neurosurg Sci.****2000;44(4):**234–7.
4. Milbouw G, Born JD, Martin D, Collignon J, Hans P, Reznik M, et al. Clinical and radiological aspects of dysplastic gangliocytoma (Lhermitte-duclos disease): A report of two cases with review of the literature. **Neurosurgery.** **1988;22(1):**124–8. DOI: 10.1227/00006123-198801000-00020
5. Yang MS, Kim CH, Cheong JH, Kim JM. Lhermitte-Duclos disease presenting with hydrocephalus. **Acta Neurochir Suppl.** **2012;(113):**161–5. DOI: 10.1007/978-3-7091-0923-6\_32
6. Pérez-Núñez A, Lagares A, Benítez J, Urioste M, Lobato RD, Ricoy JR, et al. Lhermitte-Duclos disease and Cowden disease: Clinical and genetic study in five patients with Lhermitte-Duclos disease and literature review. **Acta Neurochirurgica.** **2004;146:**679–90. DOI: 10.1007/s00701-004-0264-x
7. Yachnis AT, Rorke LB, Trojanowski JQ. Cerebellar dysplasias in humans: Development and possible relationship to glial and primitive neuroectodermal tumors of the cerebellar vermis. **J Neuropathol Exp Neurol.** **1994;53(1):**61–71. DOI: 10.1097/00005072-199401000-00008
8. Padberg GW, Schot JDL, Vielvoye GJ, Bots GTAM, de Beer FC. Lhermitte-duclos disease: a CNS manifestation of Cowden disease. **Clinical Neurology and Neurosurgery.** **1990:**189–90. DOI: 10.1016/0303-8467(90)90126-P
9. Ezgu MC, Ozer MI, Dogan A, Deveci G, Kural C, Izci Y. Lhermitte-duclos disease in a six-year old