


Twig-like MCA: A Rare Vascular Anomaly

Niharika Pant¹, Saujanya Rajbhandari², Suyasha Rajbhandari³, Saddam Ansari⁴,
Nipun Raghubanshi⁵, Pravesh Rajbhandari⁶, Basant Pant⁷

^{1,2,3,4,5,6} Annapurna Neurological Institute and Allied Sciences, Maitighar, Kathmandu, Nepal



Date of submission: 12th April 2024

Date of Acceptance: 18th April 2024

Date of publication: 15th May 2024

Abstract

Introduction : Twig-like middle cerebral artery (T-MCA) or rete mirabile anomaly is a rare vascular anomaly with clinical relevance characterized by the replacement of the M1 segment by a plexiform network of small vessels¹. With an incidence ranging from 0.11% to 1.17%, it is more prevalent in Asia.² The twig arises from the distal ICA and ends at the distal horizontal portion of MCA while lenticulostriate arteries (LSAs) arise from the plexiform network of the involved M1 segment. It is crucial to distinguish this embryological anomaly from Moyamoya Disease (MMD), moyamoya-like syndrome, atherosclerotic steno-occlusive disease, and vasculitis to prevent misdiagnosis and unnecessary treatment.² We present the case of a 30-year-old male who complained of left eyelid ptosis and diplopia. Incidentally, he was diagnosed with both a twig-like middle cerebral artery (MCA) anomaly and an associated anterior communicating artery (ACoM) aneurysm.

The twig-like middle cerebral artery (T-MCA) anomaly, also known as rete mirabile anomaly, is a rare vascular variation characterized by the replacement of the M1 segment with a plexiform network of small vessels. Here, we present a case of a 30-year-old male with left eyelid ptosis and diplopia, who was incidentally diagnosed with T-MCA anomaly along with an associated anterior communicating artery (ACoM) aneurysm.

Key words: Aneurysm, Lenticulostriate Arteries, Moyamoya Disease, Twig-like middle cerebral artery

CASE REPORT

This 30-year-old male presented with a 20-day history of sudden-onset left eyelid droop, accompanied by progressive blurry vision. On examination, left eyelid drooping and left eye medial rectus palsy were evident (Figure 1). CT cerebral angiography and digital subtraction angiography (DSA) unveiled a saccular aneurysm arising from the ACoM, involving the A2 segment of both ACAs and an absence/discontinuity of the left M1-MCA, with in-situ multiple vessels reconstituting the artery, presenting a unique "twig-like appearance" (Figure 2 and Figure 3). Patient denied surgical intervention and was subsequently managed with methylprednisolone and supportive measures, maintaining stable vitals and fair general condition throughout

the hospital stay. Upon discharge, the patient was prescribed oral medications (Prednisolone, Pyridostigmine, Methylcobalamine, Esmoprazole) and scheduled for a follow-up after six months for repeat angiography to monitor the size of the ACoM aneurysm.

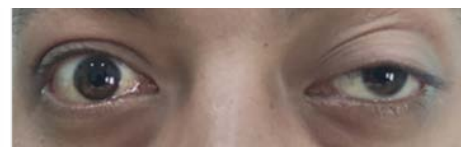

Figure 1. Initial presentation of patient with sudden onset left eyelid droop.

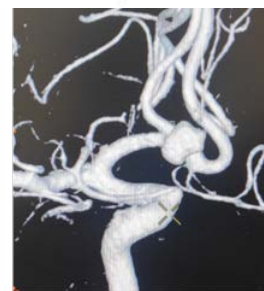


Figure 2. 3D rotational angiography showing incidental anterior communicating artery aneurysm.

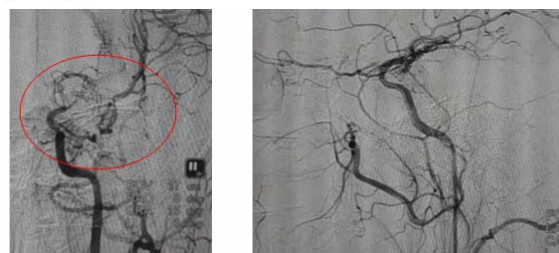

Figure 3. Left internal carotid artery angiography ((a) AP view and (b) lateral view) showing twig-like MCA (red circle).

Access this article online

Website: <https://www.nepjol.info/index.php/NJN>

DOI: <https://doi.org/10.3126/njn.v21i1.64692>

HOW TO CITE

Pant N, rajbhandari saujanya, Rajbhandari S, Rajbhandari S, Ansari S, Raghubanshi N, Rajbhandari P, Pant B. Twig-like MCA: A Rare Vascular Anomaly. NJNS. 2024;21(1):36-37

Address for correspondence:

Saujanya Rajbhandari
Annapurna Neurological Institute and Allied Sciences,
Maitighar, Kathmandu, Nepal
Email: saujanyaajbhandari.sr@gmail.com

Copyright © 2023 Nepalese Society of Neurosurgeons (NESON)

ISSN: 1813-1948 (Print), 1813-1956 (Online)



This work is licensed under a Creative Commons Attribution-Non Commercial 4.0 International License.

Discussion

MCA anomalies are relatively rare, however, duplicated, accessory, duplicated origin, early branching, fenestrated, and twig-like MCA have been reported. There are only a few reported cases of twig-like MCA which have also been described as “unfused MCA”, “aplastic MCA”, and “unfused/twig-like MCA”.

Twig-like MCA is generally due to an unknown mechanism or ischemic insult in utero. Twig-like MCA is considered a “persistent” arterial network of primitive MCA due to regression failure³ (Figure 4). However, there is no evidence showing that twig-like MCA is the persistent embryonal arterial network.

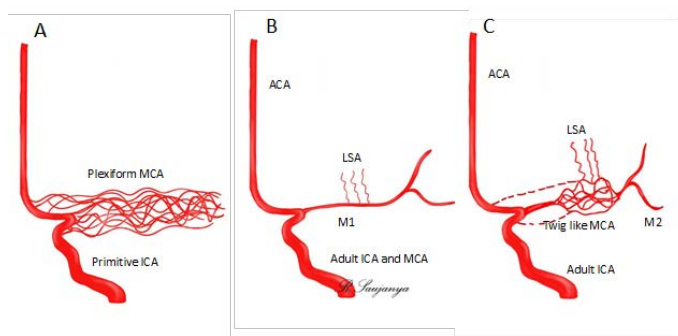


Figure 4. Illustration showing the formation of normal MCA and Twig-like MCA from Primitive ICA. A) Primitive ICA giving rise to plexiform MCA. B) Plexiform networks develop into adult MCA. C) Persistent twigs of primitive MCA forming twig-like MCA.

Angiographical features of twig-like MCA include 1) a stenooclusive lesion at the unilateral MCA 2) a plexiform arterial network replacing normal MCA 3) LSAs arising from the plexiform arterial network 4) normal cortical branches beyond the affected MCA trunk and 5) compensatory leptomeningeal collaterals from anterior and posterior cerebral arteries.³

Anomalies in the twig-like middle cerebral artery (T-MCA) have been found to correlate with various stroke types. Ischemic strokes are reported in 33–46% of cases, while hemorrhagic strokes occur in 27–40% of cases. Additionally, T-MCA anomalies are implicated in aneurysm rupture in 26.6–46% of cases.⁴ Aneurysm formation is a well-documented complication of T-MCA, commonly at the distal ICA, or the A1-A2 junction of the ACA, hinting at their flow-related nature. The reported case also demonstrated an anterior communicating artery aneurysm (Figure 2)

T-MCA must be differentiated from MMD and other steno-occlusive disorders of the arterial circle of Willis including MCA. It is important to distinguish the differences in angioarchitecture to prevent mistreatment. Additionally, while 20%–43% of MMD cases involve the PCA, T-MCA typically shows no posterior circulation involvement.⁵ Also, while MMD progresses, twig-like MCA was recognized to be non-progressive during the reported short periods. Mutation in the gene encoding RNF213 is the strongest genetic

factor for MMD in the East Asian population. There has also been a reported case of twig-like MCA showing a heterozygous mutation of RNF213.3 Further genetic investigations are warranted to know the underlying common pathogenesis of MMD and twig-like MCA.

Conclusion

In conclusion, T-MCA anomalies present complex clinical challenges, with risks of both ischemic and hemorrhagic strokes, as well as aneurysm formation. While distinguishing T-MCA from other cerebrovascular conditions like MMD is crucial for accurate diagnosis and appropriate treatment, uncertainties persist regarding optimal management strategies. Further research is needed to elucidate the effectiveness of interventions such as antiplatelet medications and revascularization procedures in reducing the associated risks, highlighting the importance of continued investigation into this rare vascular anomaly.

Reference

1. Onoue, K., Nguyen, T.N., Mian, A., Dasenbrock, H., Bedi, H. and Abdalkader, M., 2021. Twig-like middle cerebral arteries: clinical and radiological findings. *Clinical Imaging*, 73, pp.31-37. doi: 10.1016/j.clinimag.2020.11.049.
2. Lo Vullo G, Danieli L, Distefano D, Occhipinti M, Cianfoni A. 'Twig-like' middle cerebral artery. *Eurorad*. 2021;17217. doi: .35100/eurorad/case.17217
3. Ota T, Komiyama M. Twig-like middle cerebral artery: Embryological persistence or secondary consequences? *Interventional Neuroradiology*. 2021 Aug;27(4):584-7. doi: 10.1177/15910199211024077
4. Serrano-Rubio A, Ferrufino-Mejia BR, Balcázar-Padrón JC, Rodríguez-Rubio HA, Nathal E. Ruptured aneurysm associated with a twig-like middle cerebral artery: An illustrative case report. *Surgical Neurology International*. 2022;13. doi: 10.25259/SNI_678_2022
5. Goto Y, Nanto M, Oka H, Murakami N, Nakagawa T, Kimura S, Iwamoto Y, Inoue Y, Matsumoto K, Miyamoto J, Hashimoto N. Radiological and clinical features of twig-like middle cerebral artery in comparison with moyamoya angiopathy: a multicenter retrospective study. *J Neurosurg*. 2022 Apr 15;137(6):1718-1726. doi: 10.3171/2022.2.JNS212338.